

Robotic First Rib Resection



Bryan M. Burt, MD, FACS
Professor & Chief
Division of Thoracic Surgery



Feature Editor
The Journal of Thoracic and Cardiovascular Surgery



ATCSA2023
Ho Chi Minh city, Vietnam



Disclosures

Investigator-Initiated Clinical Trial Funding

AstraZeneca for NCT02592551

Momotaro-Gene for NCT04013334

Novartis for NCT04492891

Research Funding

NIH: R01CA284742, R37CA248478

CPRIT: RP190522, RP200443, RR170048

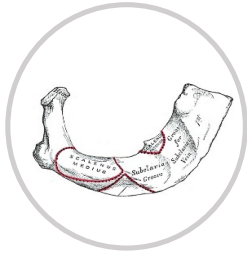
Owner, Intellectual Property, Board Member



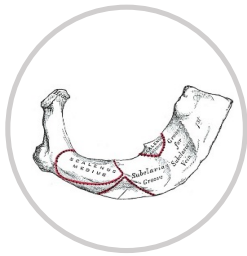Industry Collaboration

Intuitive Surgical (proctor)

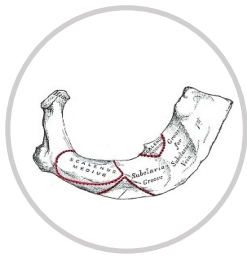
AstraZeneca (speaker), Momotaro-Gene (lab)



Background & Rationale

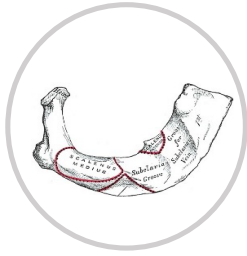


Operation (3 cases)

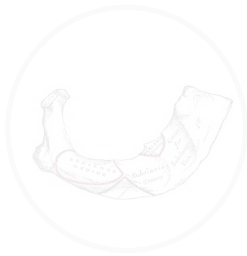

Results

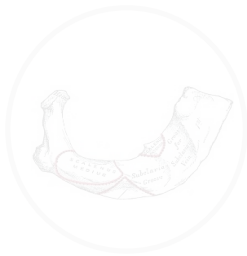



Background & Rationale



Operation (3 cases)



Results



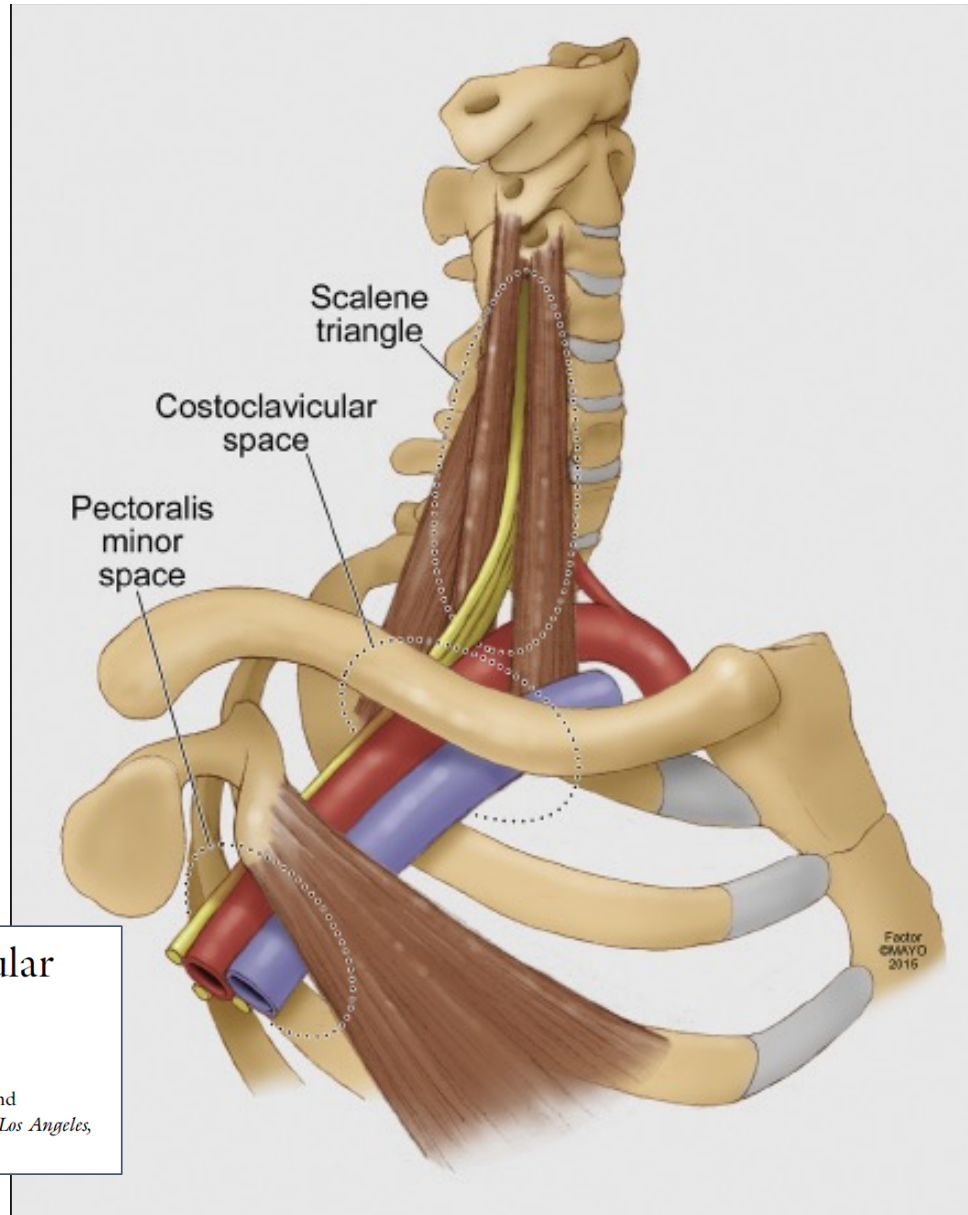
TOS: Three Syndromes

A group of 3 disorders all having in common compression at the thoracic outlet

Three structures are at risk:

1. brachial plexus producing neurogenic (nTOS)
2. subclavian vein producing venous (vTOS)
3. subclavian artery producing arterial (aTOS)

Anatomy

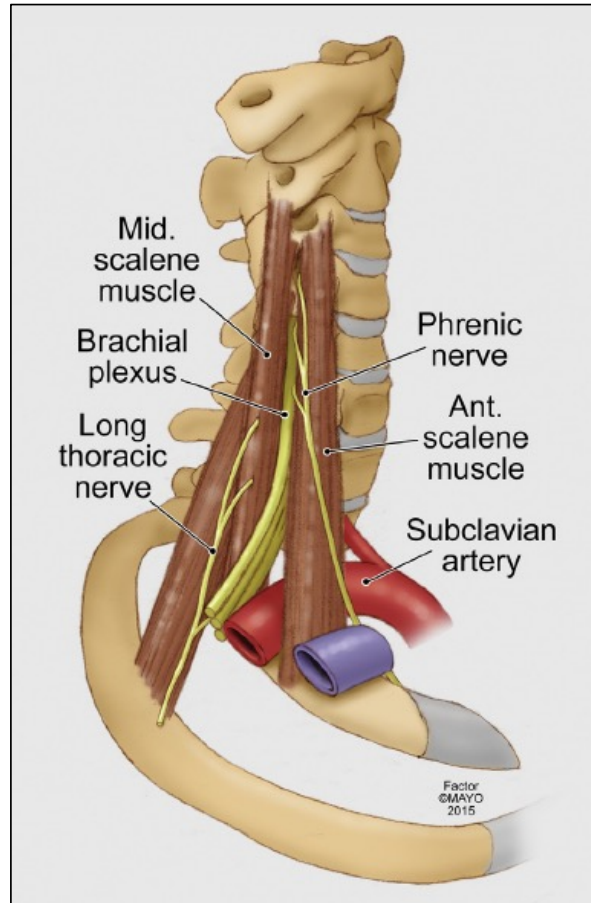


J Vasc Surg 2016; 64:e23

Reporting standards of the Society for Vascular Surgery for thoracic outlet syndrome

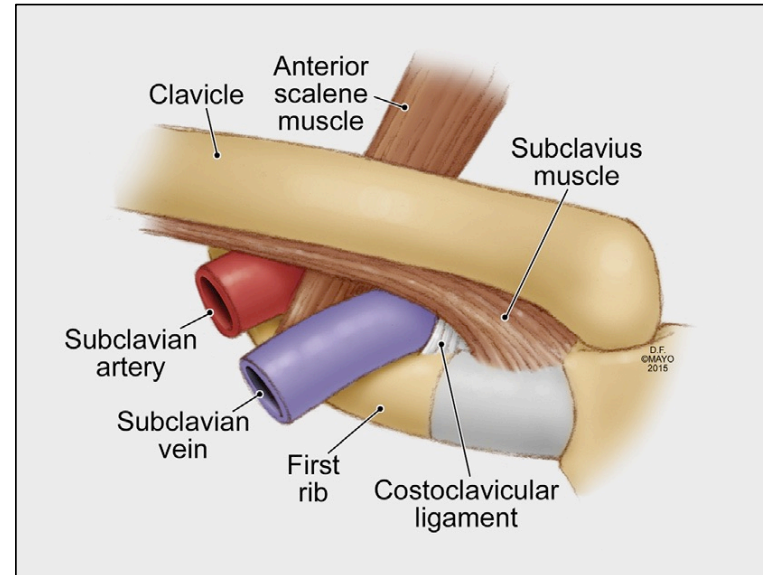
Karl A. Illig, MD,^a Dean Donahue, MD,^b Audra Duncan, MD,^c Julie Freischlag, MD,^d Hugh Gelabert, MD,^e Kaj Johansen, MD,^f Sheldon Jordan, MD,^g Richard Sanders, MD,^h and Robert Thompson, MD,ⁱ *Tampa, Fla; Boston, Mass; London, Ontario, Canada; Sacramento and Los Angeles, Calif; Seattle, Wash; Aurora, Colo; and St. Louis, Mo*

Anatomy



1. Scalene Triangle

nTOS (+aTOS)



2. Costoclavicular Space

vTOS

TOS Surgery = Decompression

First Rib Resection & Scalenectomy

- **10 approaches:** Supraclavicular, infraclavicular, paraclavicular, transaxillary, VATS transaxillary, VATS transthoracic, VATs transaxillary, robotic transthoracic, robotic transaxillary, posterior
- **5 Specialties:** Vascular (90%)*, thoracic, plastics, neurosurgery, orthopedics

*JVS2017 Rinehardt (NSQIP)

Robotic Transthoracic FRR

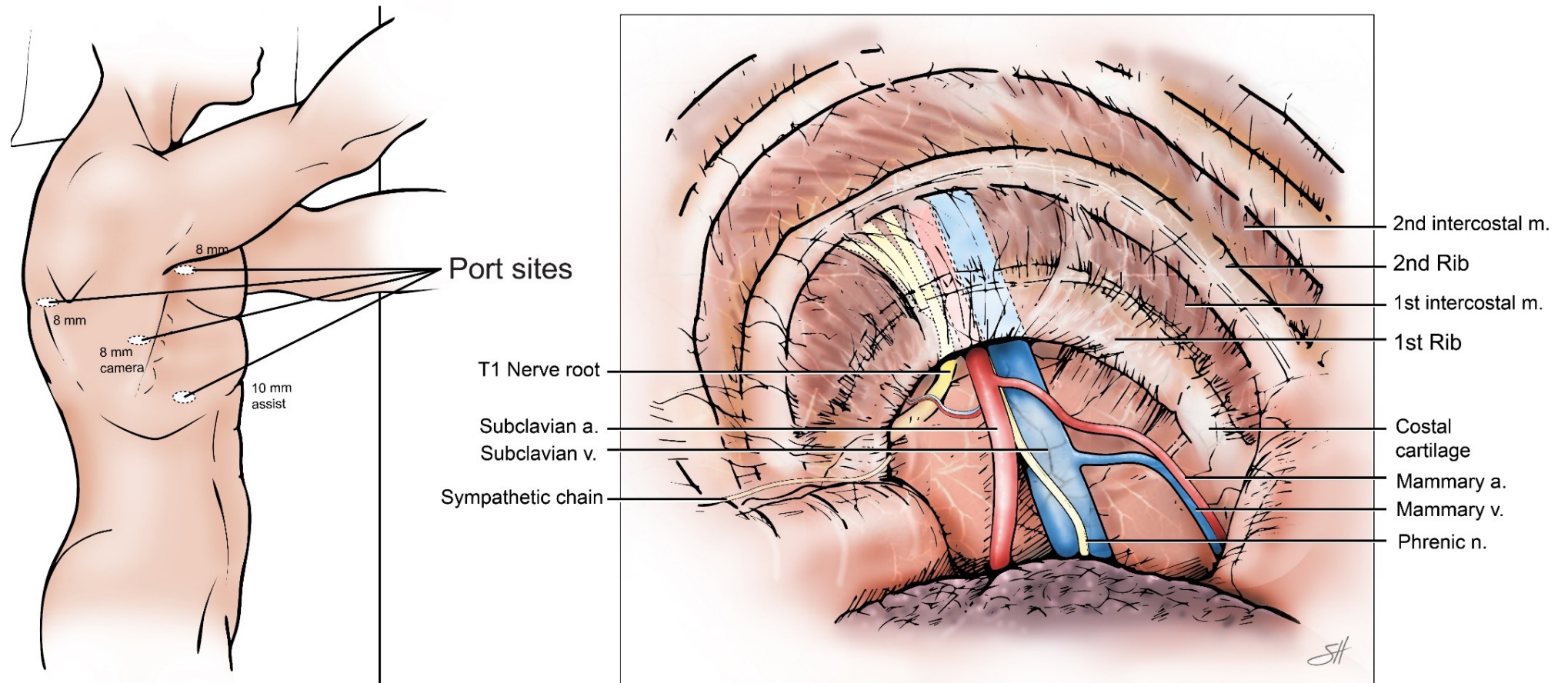
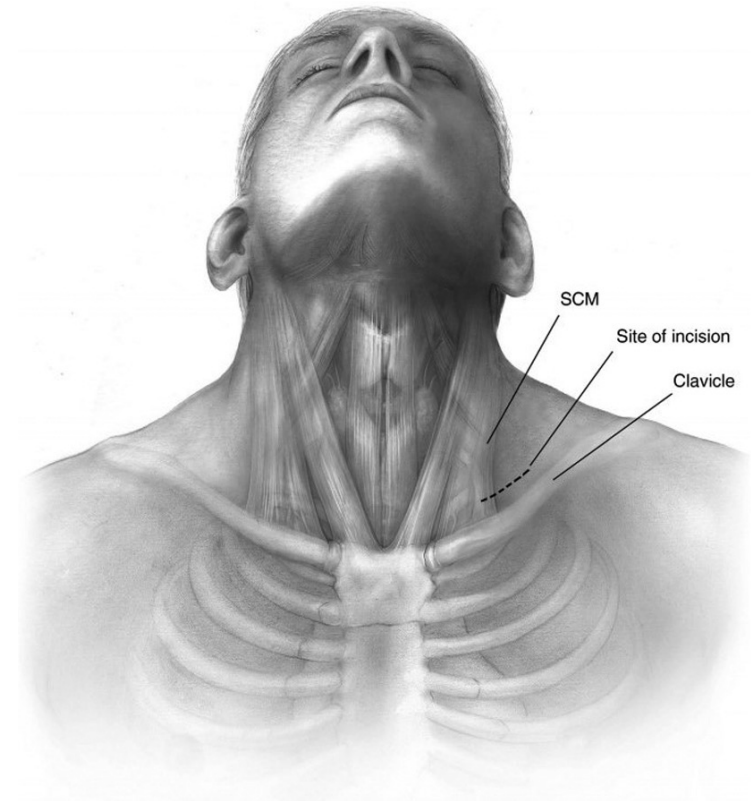
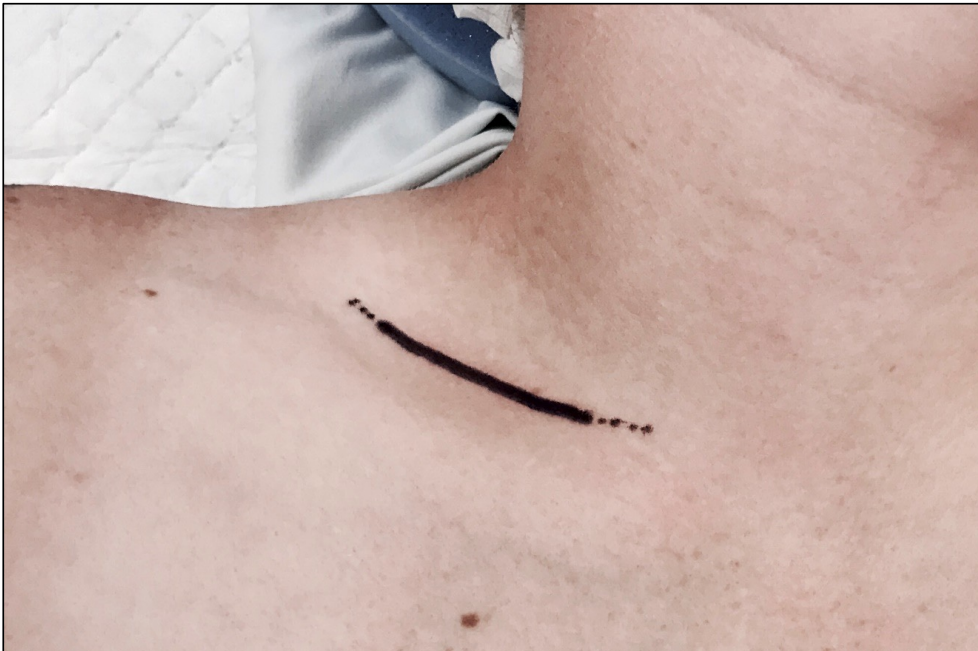

Illustration: Scott Holmes, BCM

Advantages of Robotic FRR

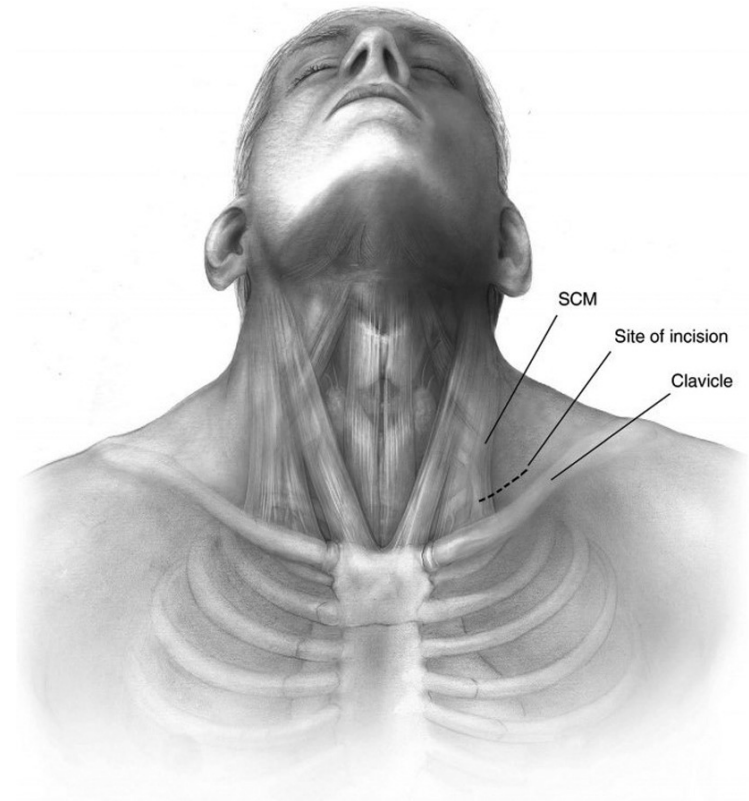
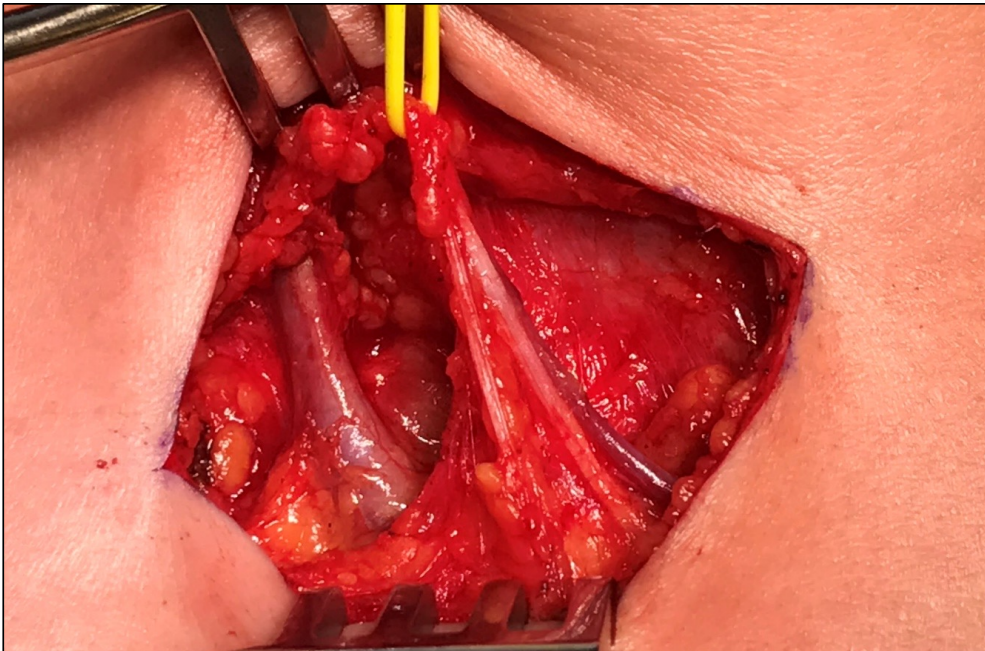
Supraclavicular Approach



Broussard & Donahue. Thor Surg Clin 2021

Advantages of Robotic FRR

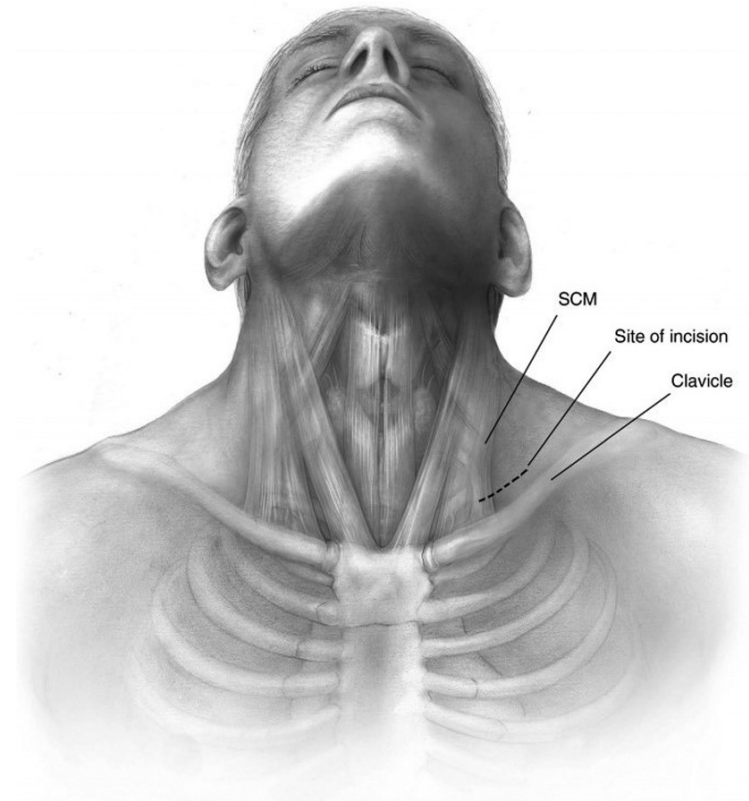
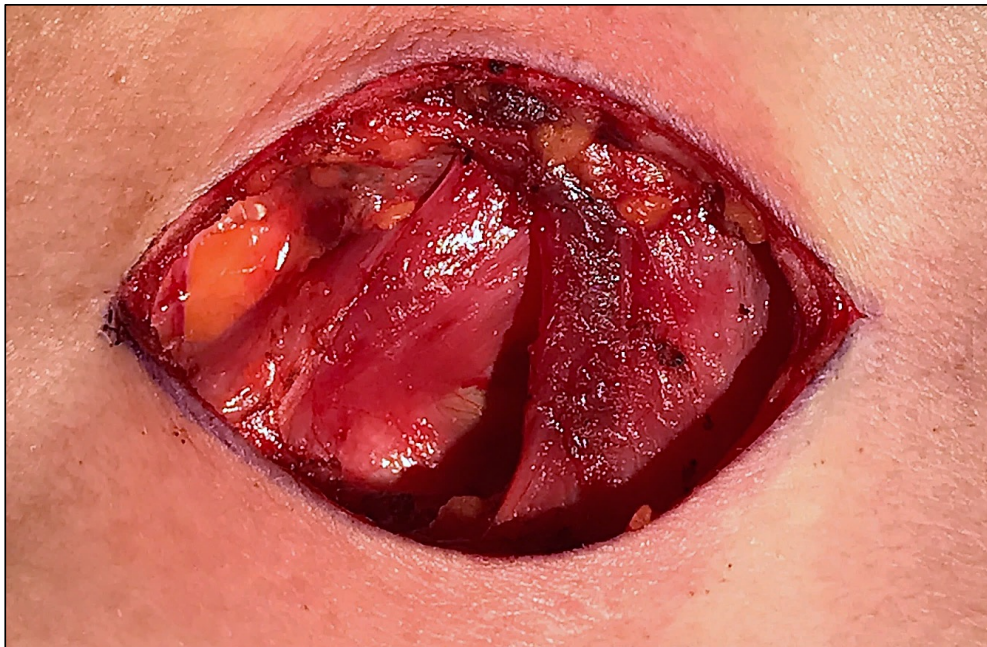Supraclavicular Approach



Broussard & Donahue. Thor Surg Clin 2021

Advantages of Robotic FRR

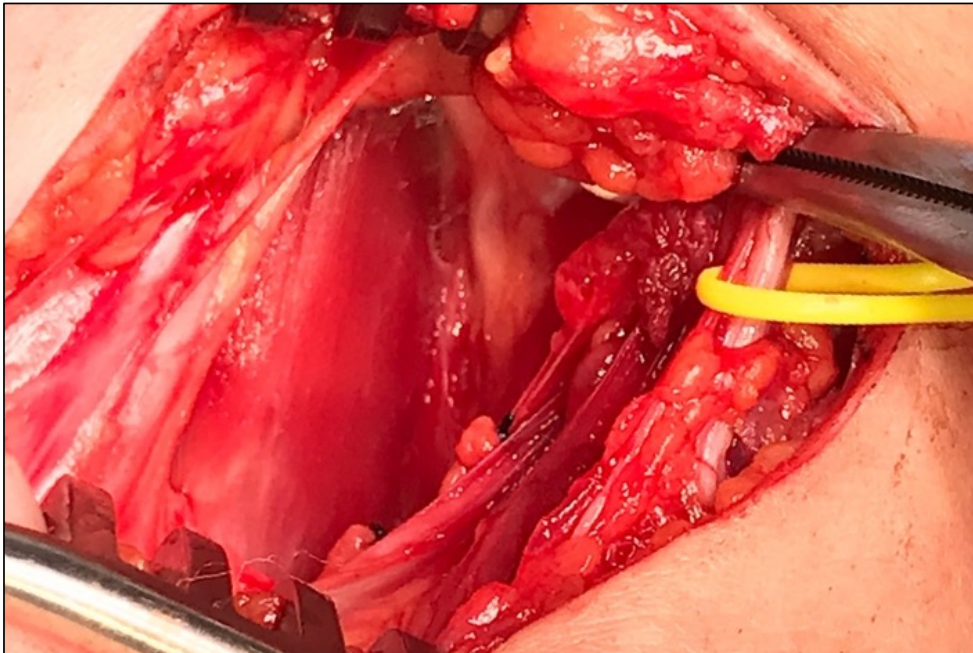
Supraclavicular Approach



Broussard & Donahue. Thor Surg Clin 2021

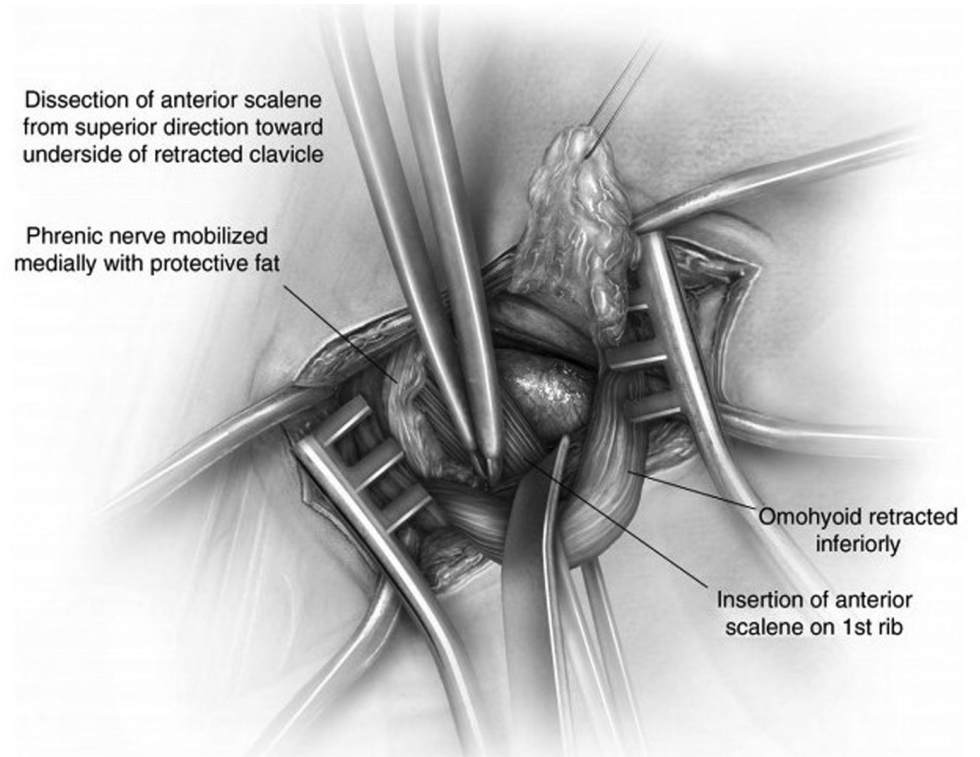
Advantages of Robotic FRR

Supraclavicular Approach



Dissection of anterior scalene from superior direction toward underside of retracted clavicle

Phrenic nerve mobilized medially with protective fat

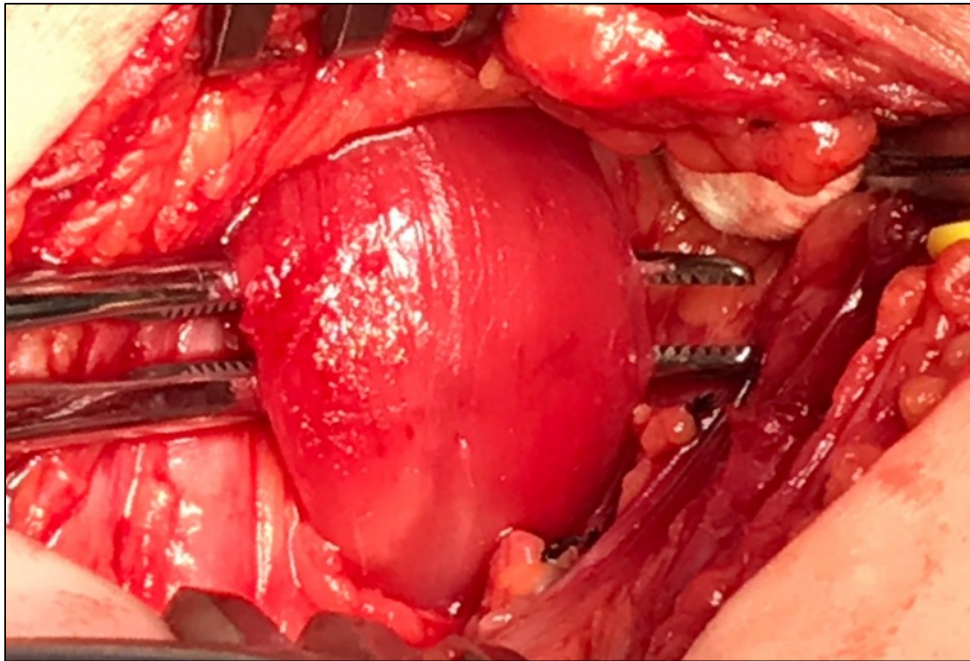


Omohyoid retracted inferiorly

Insertion of anterior scalene on 1st rib

Advantages of Robotic FRR

Supraclavicular Approach

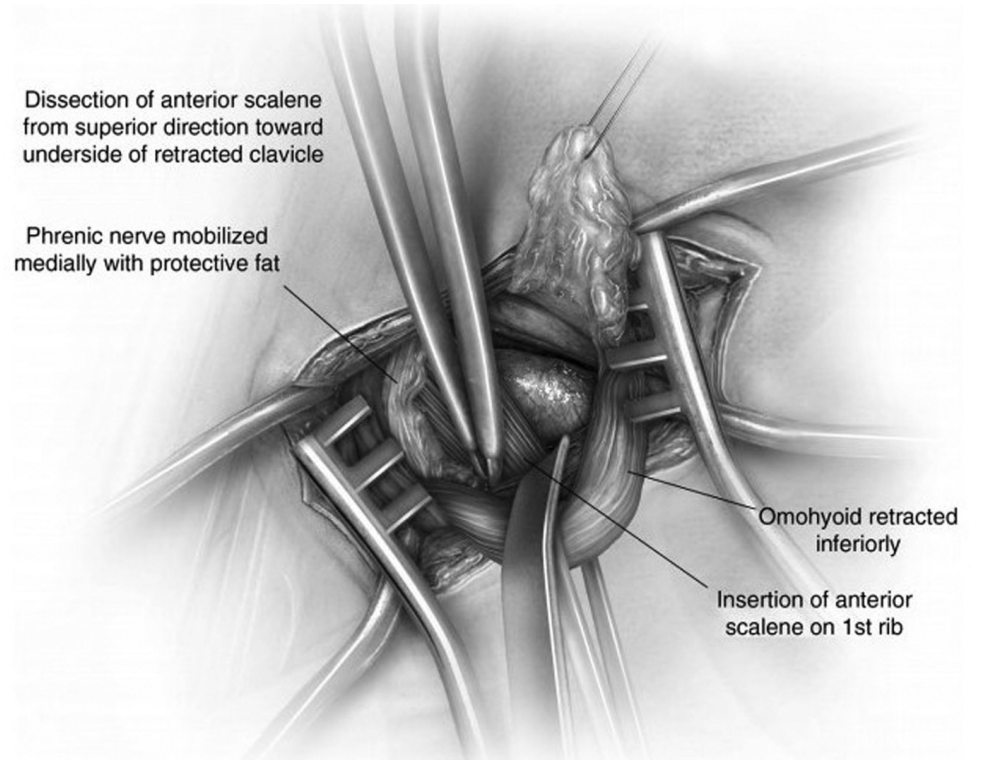


Dissection of anterior scalene from superior direction toward underside of retracted clavicle

Phrenic nerve mobilized medially with protective fat

Omohyoid retracted inferiorly

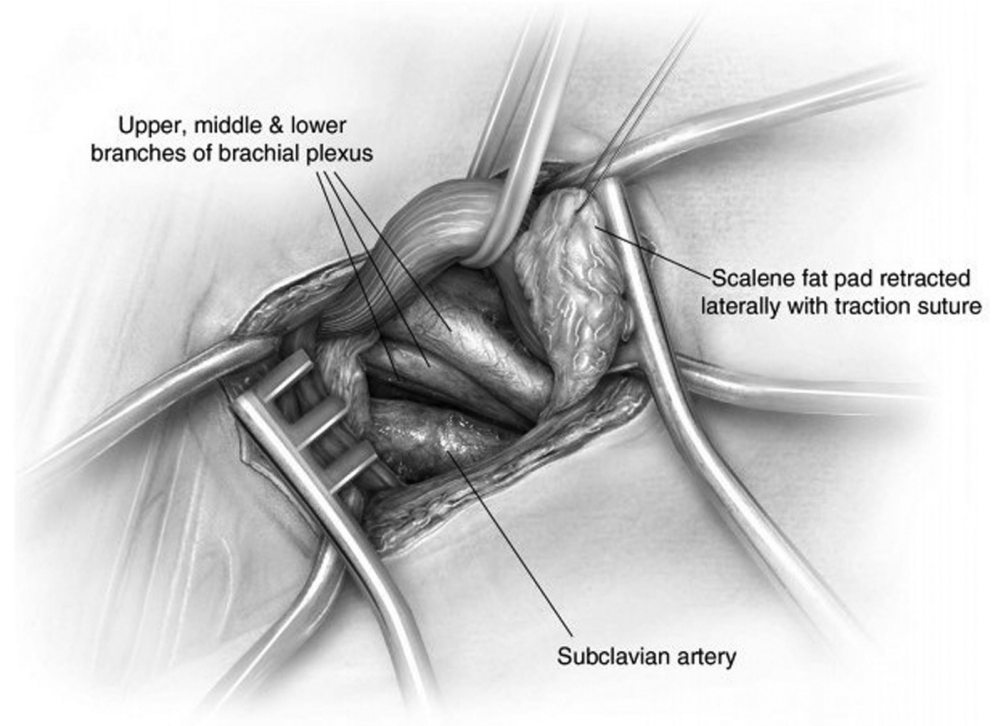
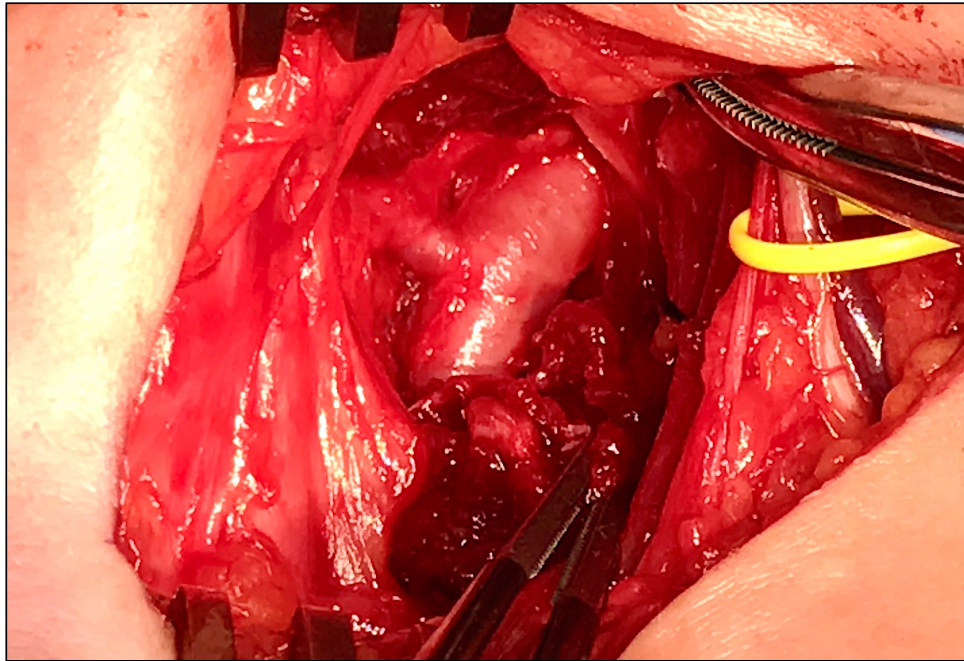
Insertion of anterior scalene on 1st rib



Broussard & Donahue. Thor Surg Clin 2021

Advantages of Robotic FRR

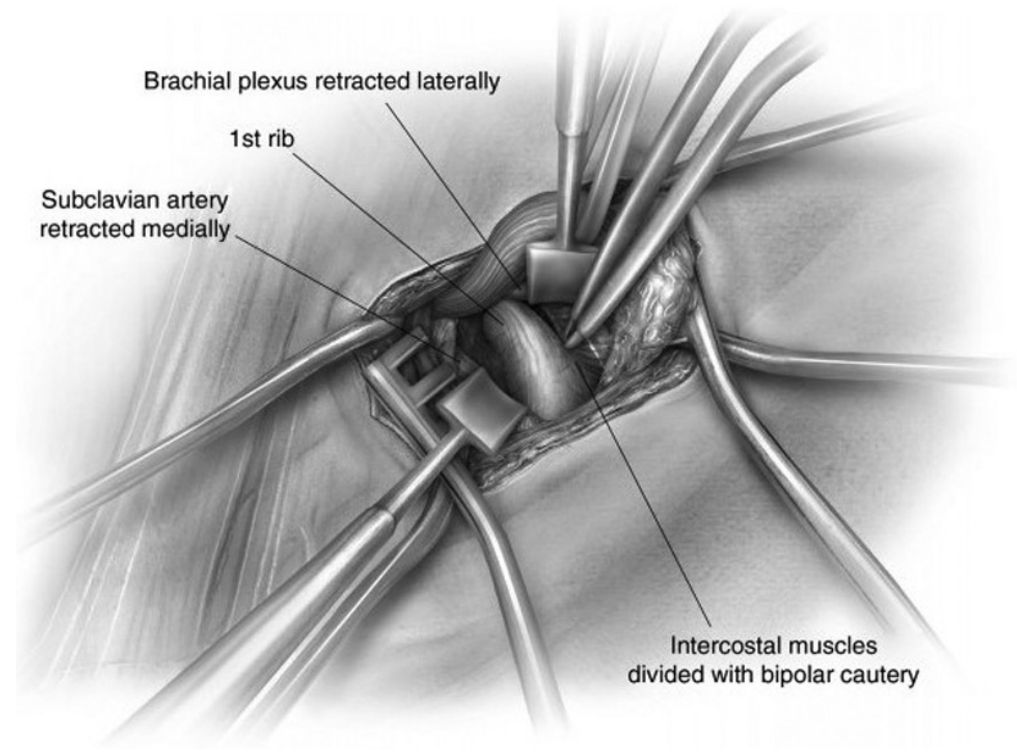
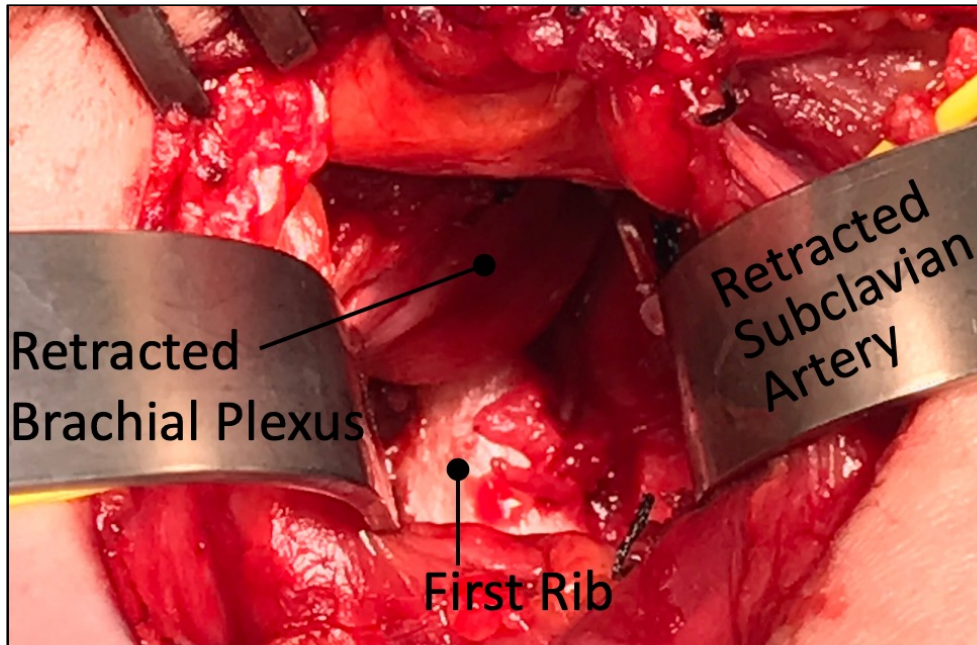
Supraclavicular Approach



Broussard & Donahue. Thor Surg Clin 2021

Advantages of Robotic FRR

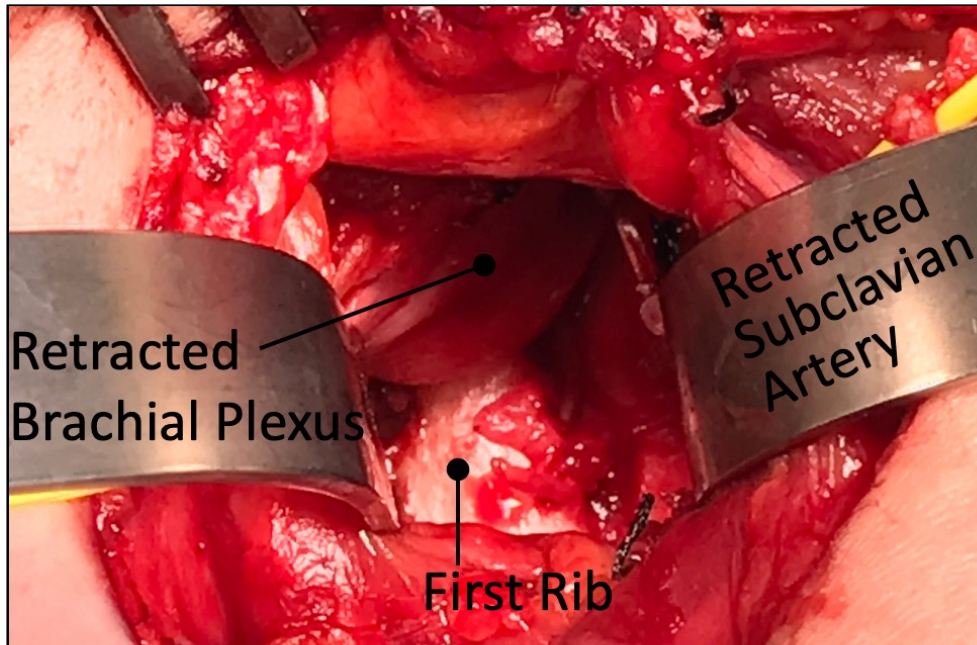
Supraclavicular Approach



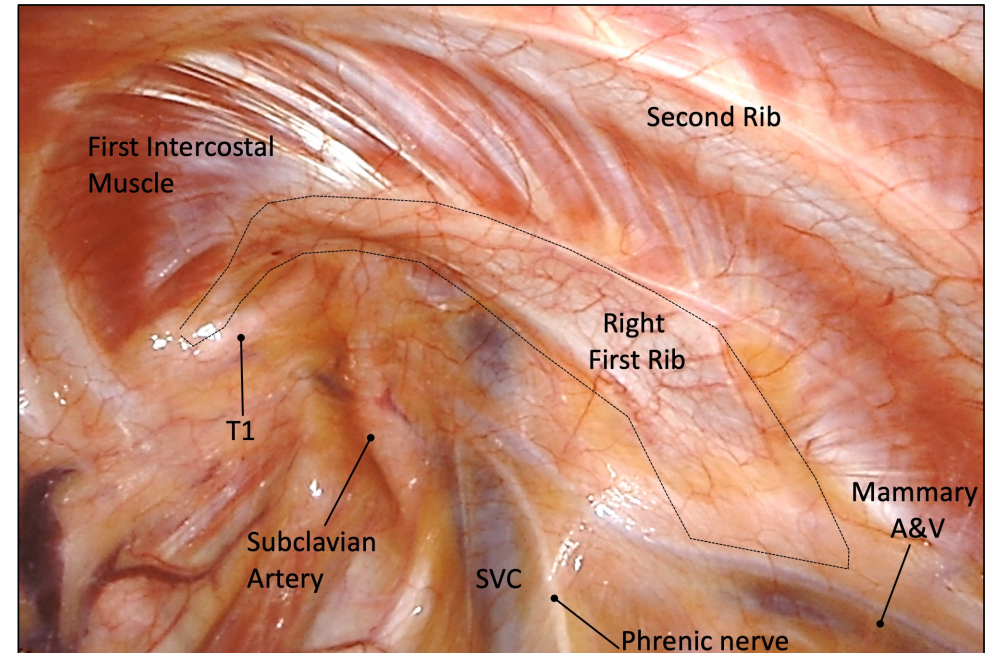
Broussard & Donahue. Thor Surg Clin 2021

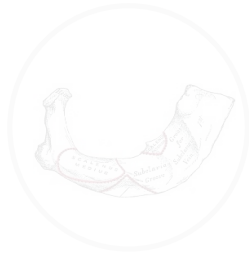Advantages of Robotic FRR

Supraclavicular Approach

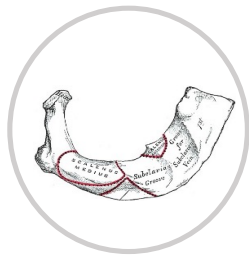

Robotic Transthoracic Approach

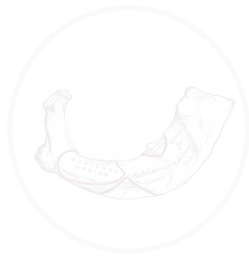



Background & Rationale



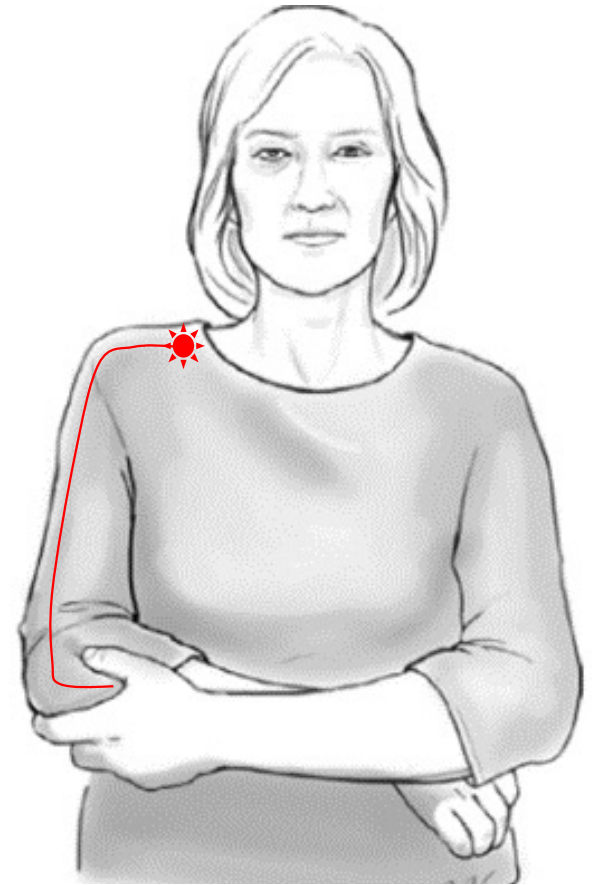
Operation (3 cases)



Results

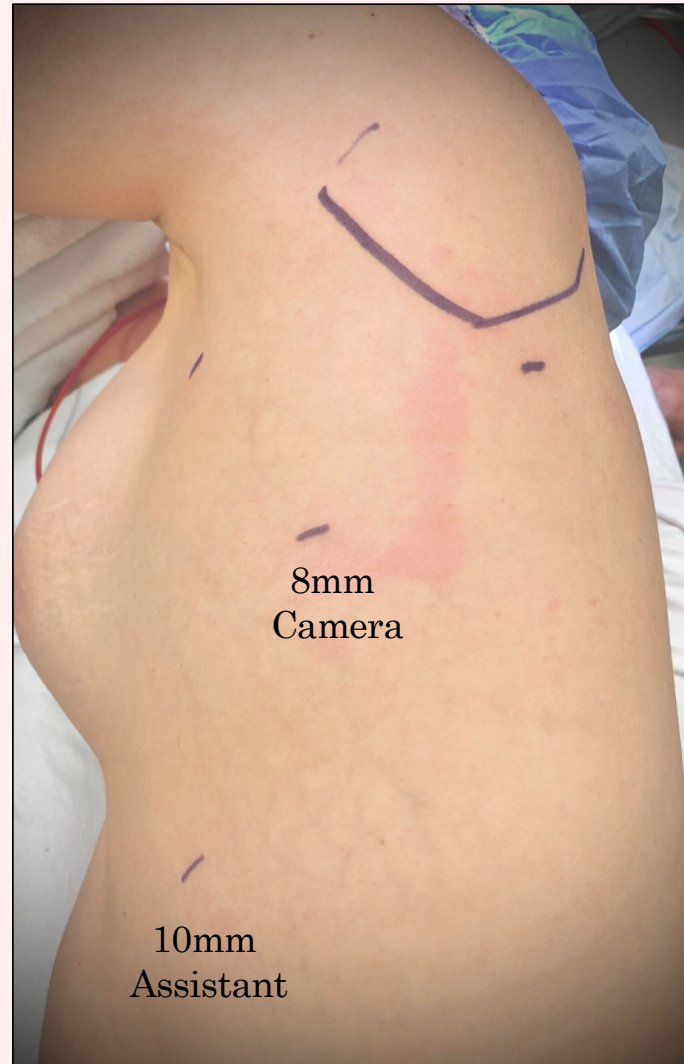


nTOS



1. Placement of Ports

8mm
Working Port

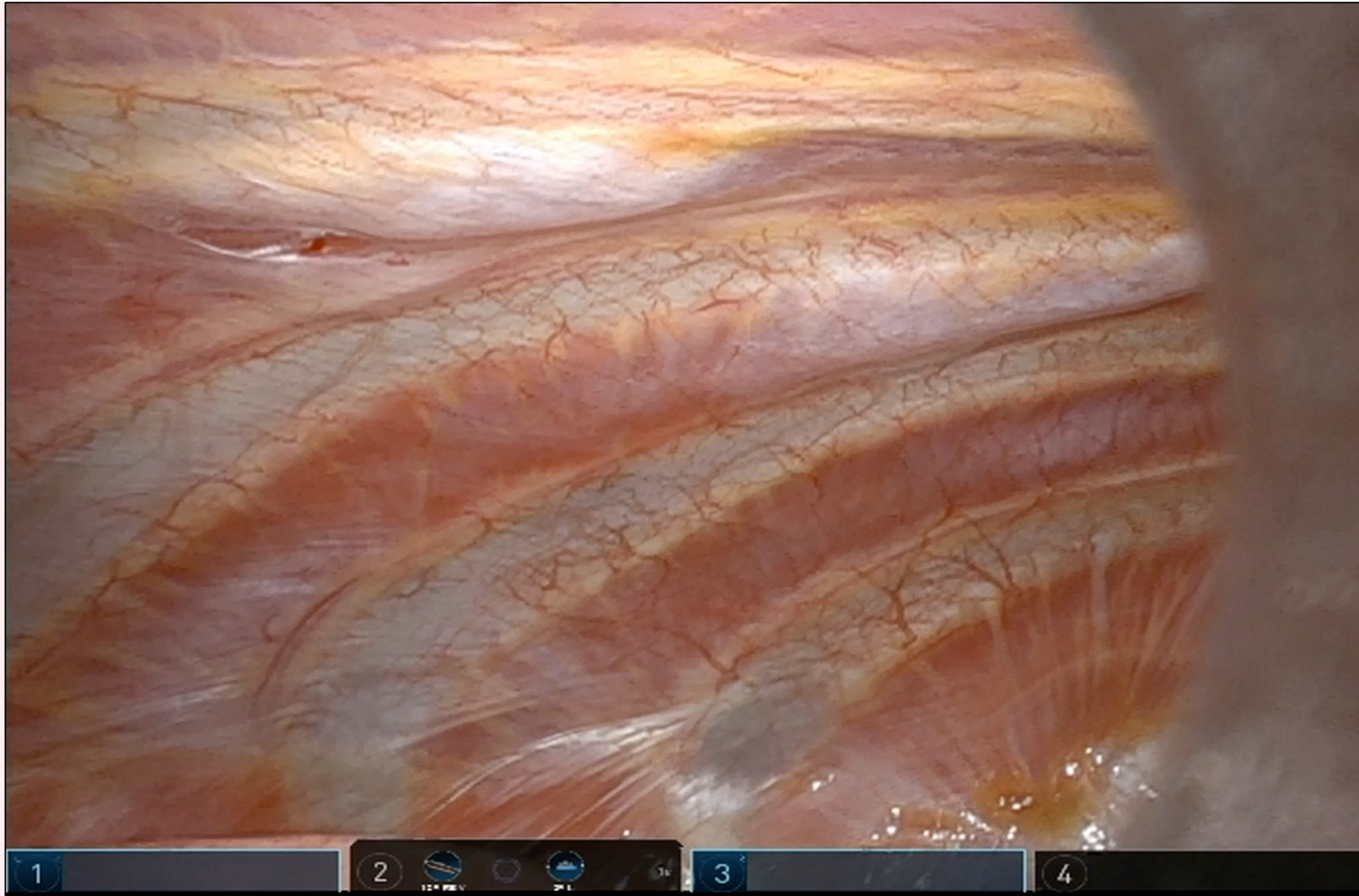


8mm
Working Port

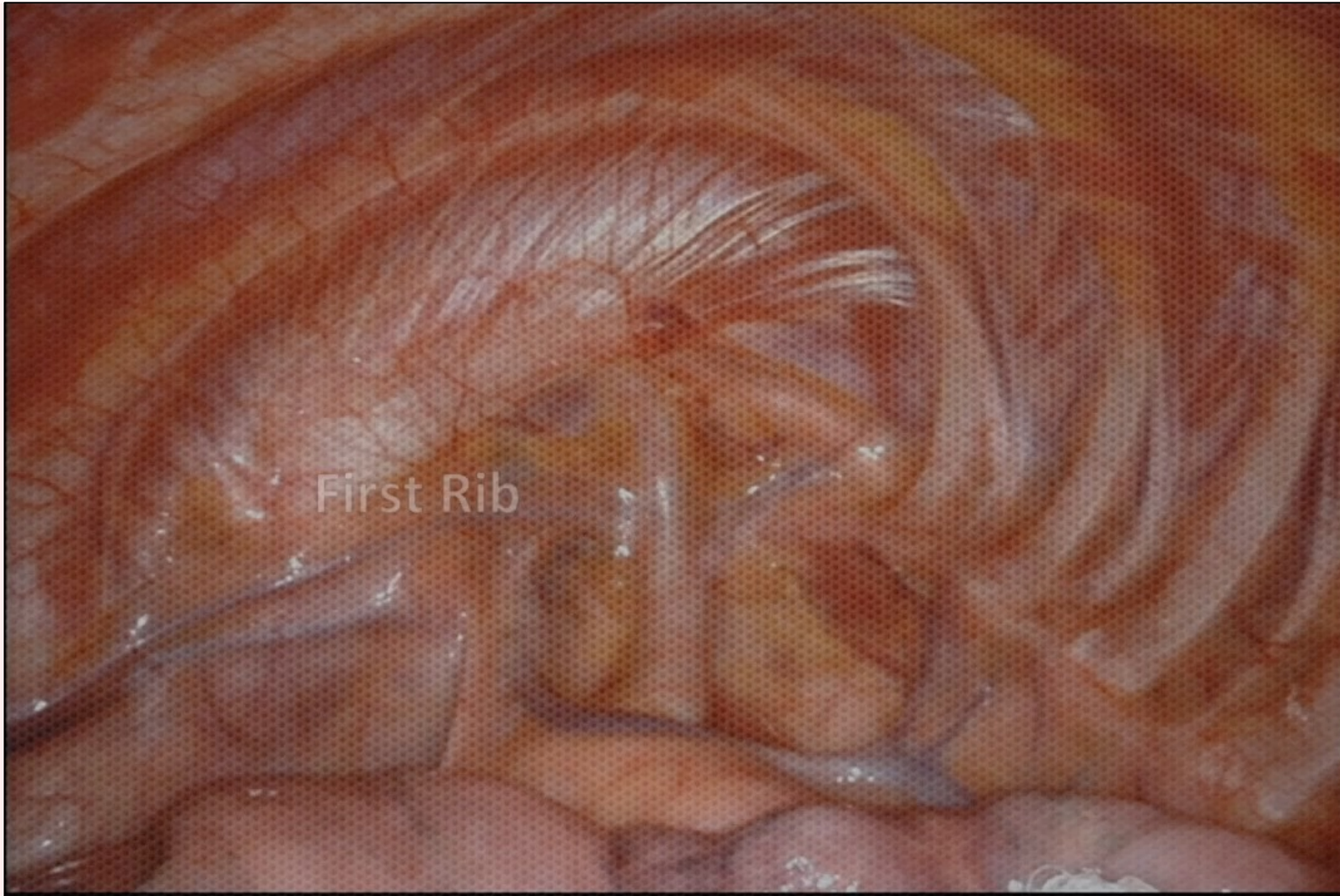8mm
Camera

10mm
Assistant

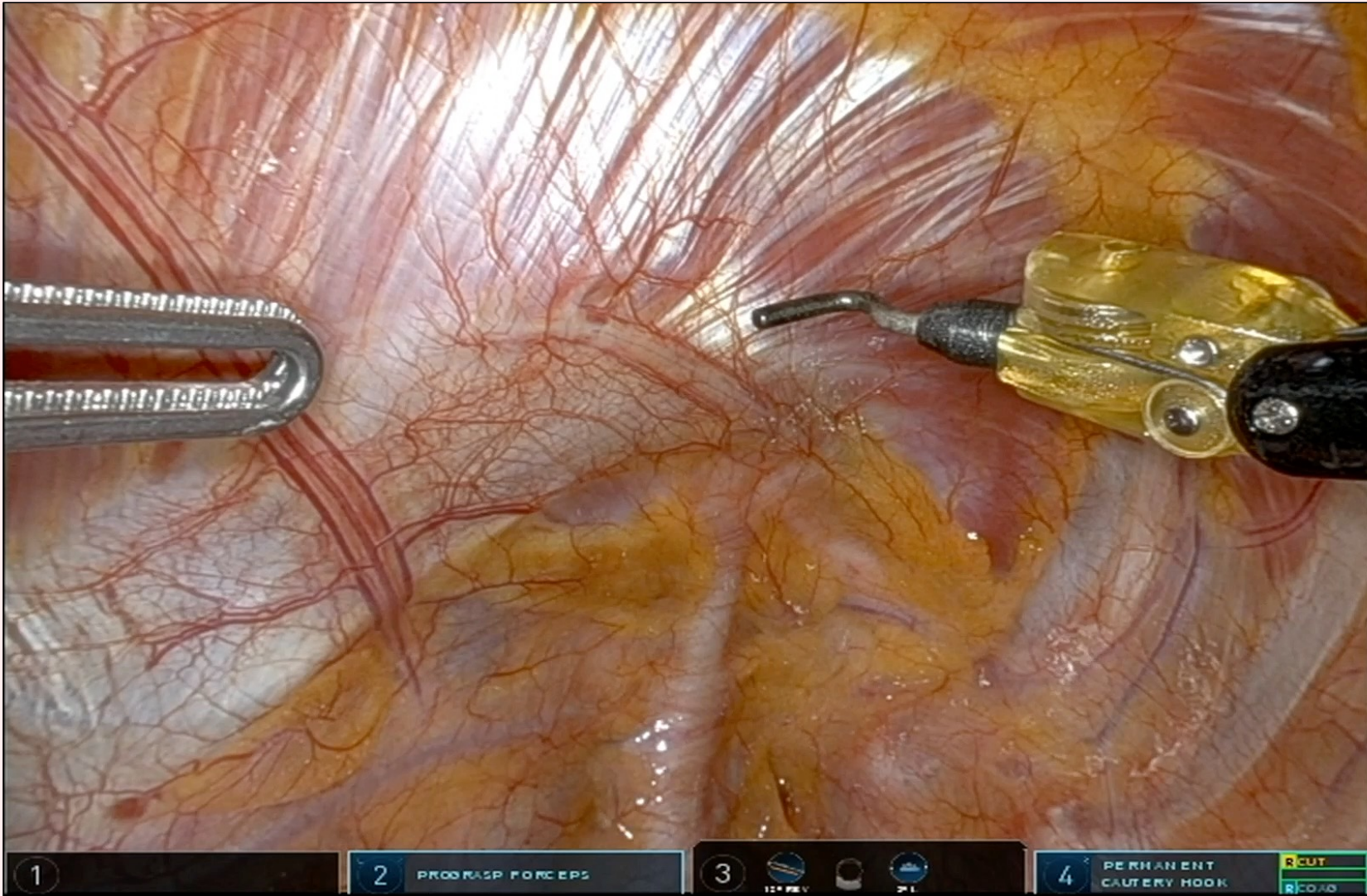1. Placement of Ports



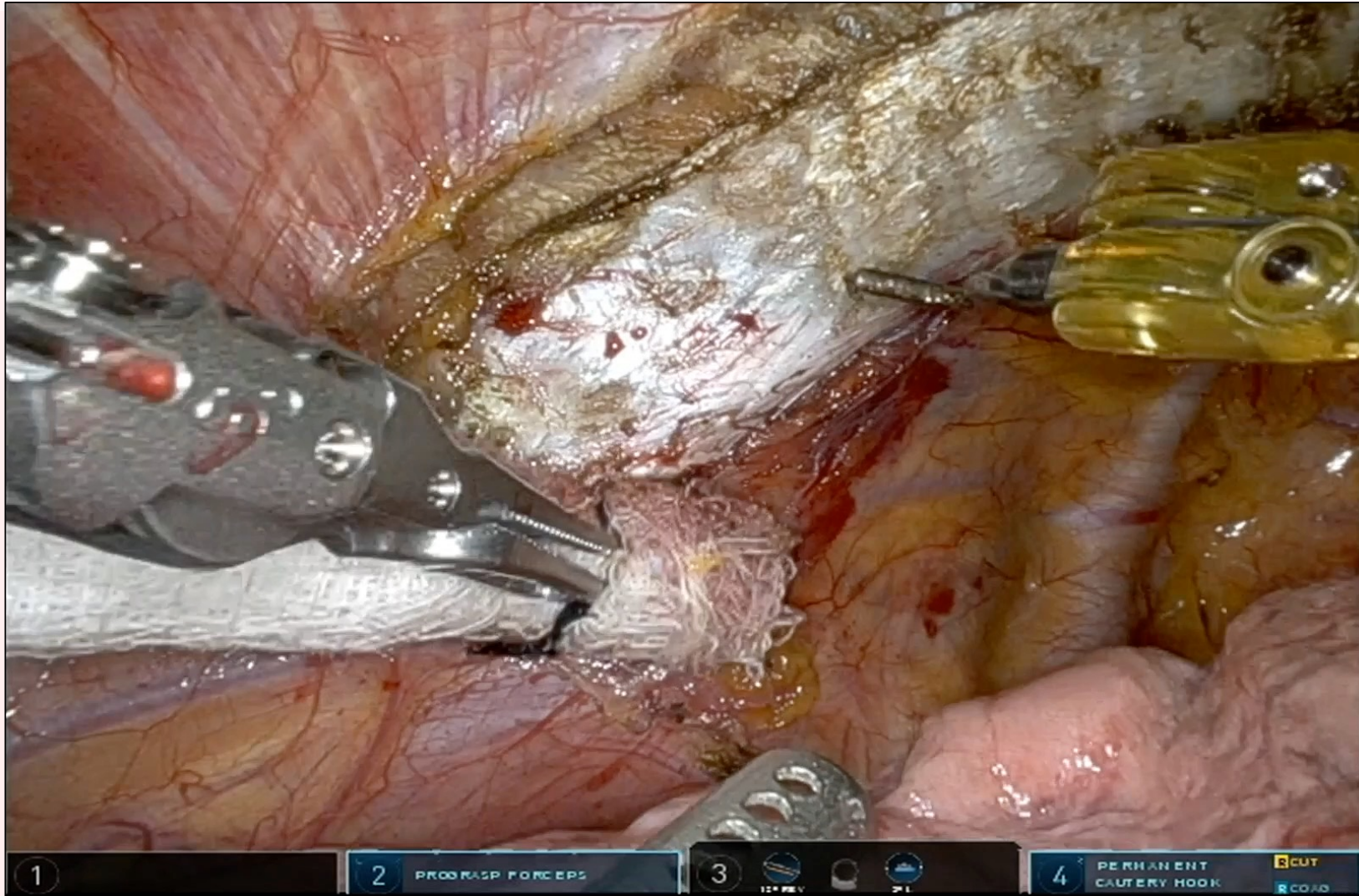
2. Survey of Anatomy



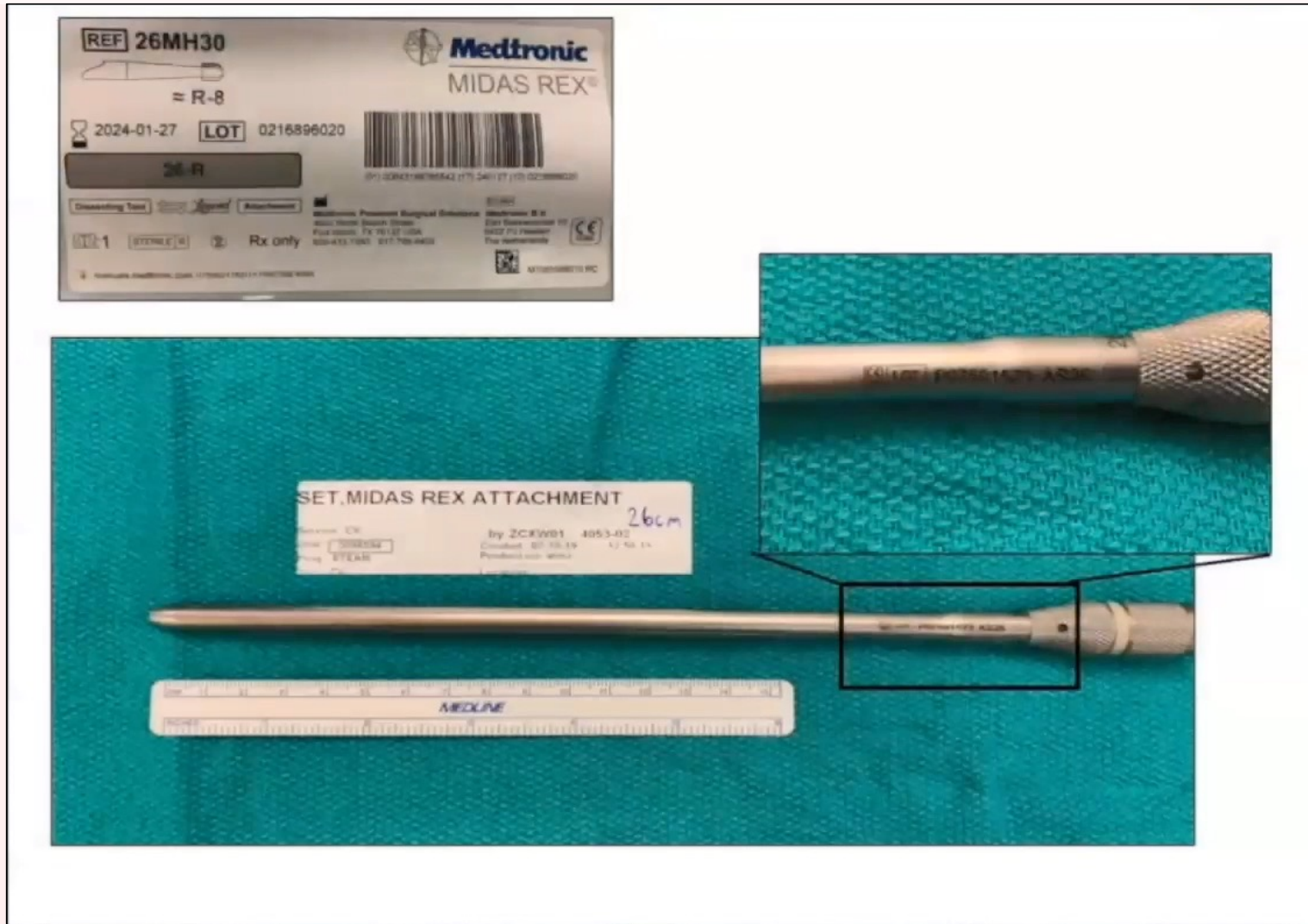3. First Intercostal Muscle



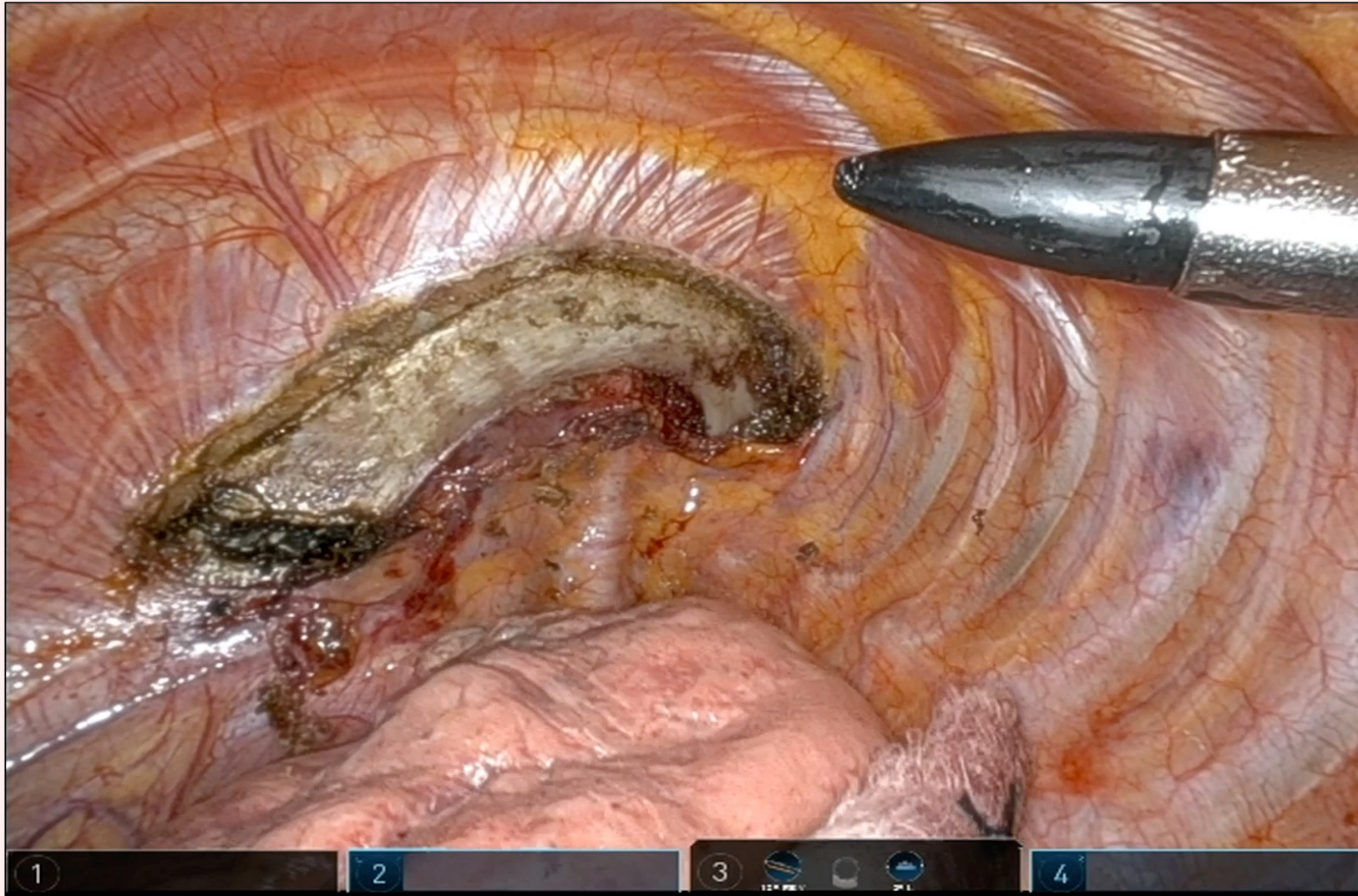
4. Division of Costal Cartilage & Preparation of Posterior Rib



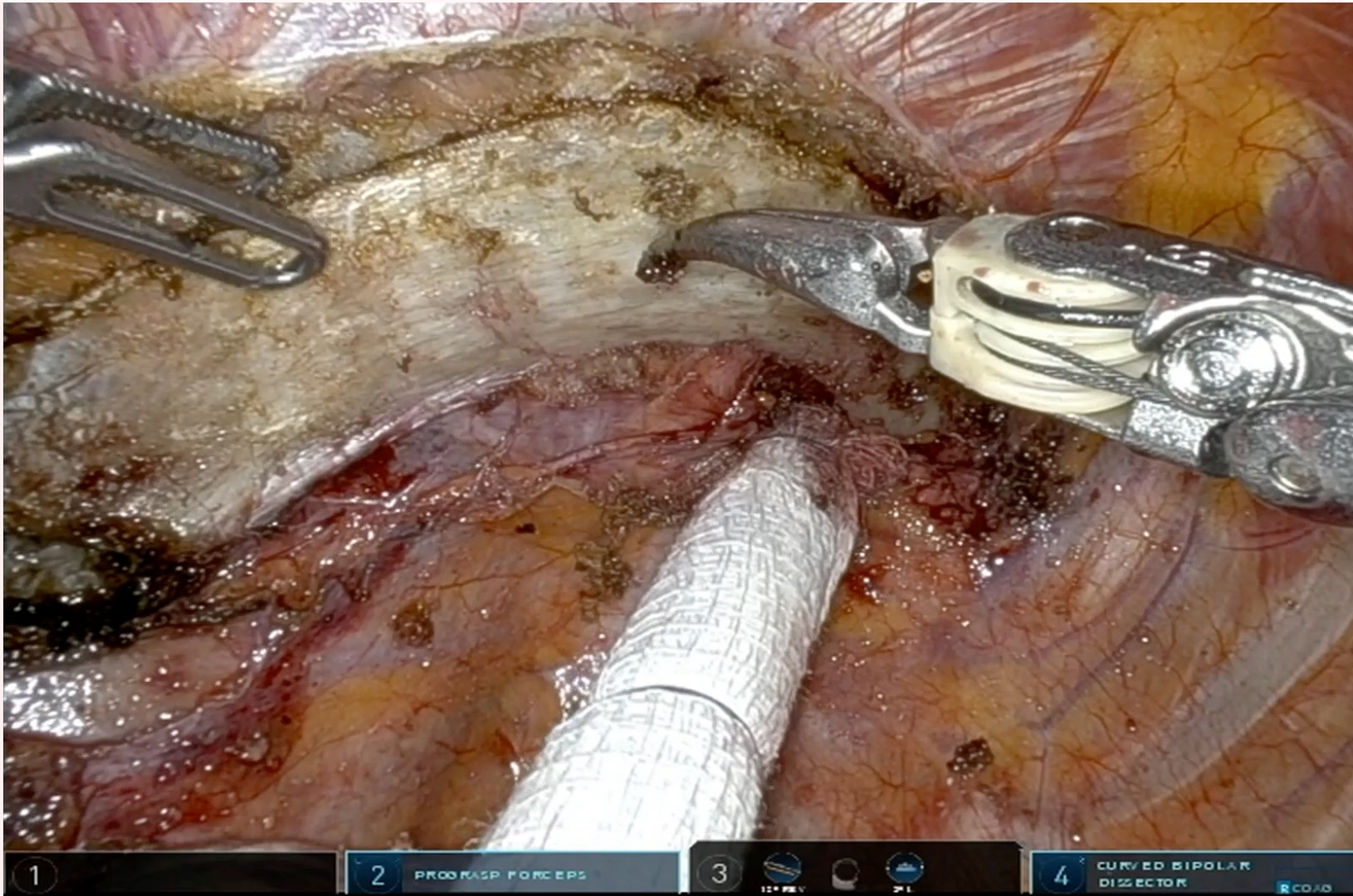
5. Division of Posterior Rib



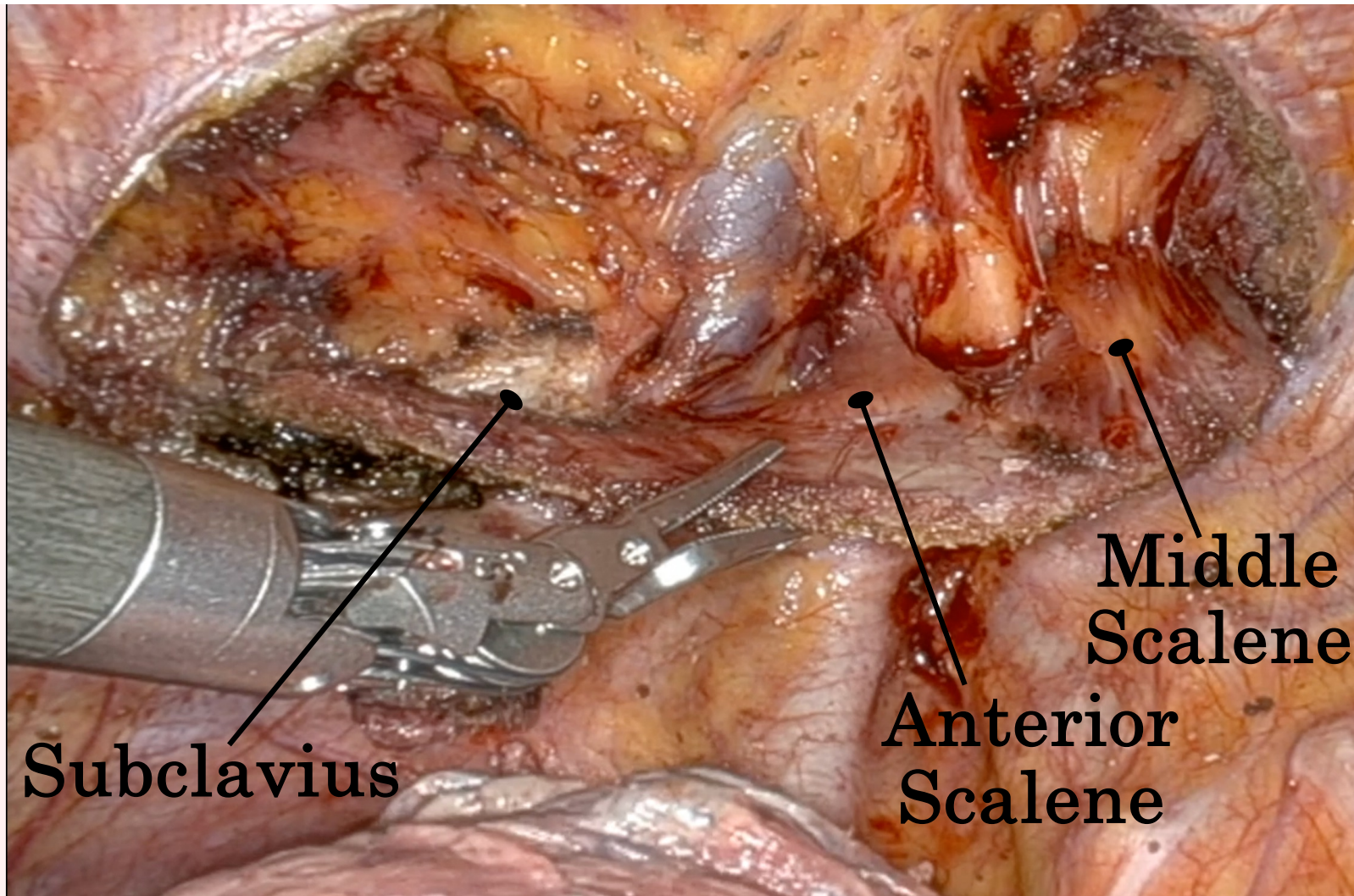
5. Division of Posterior Rib



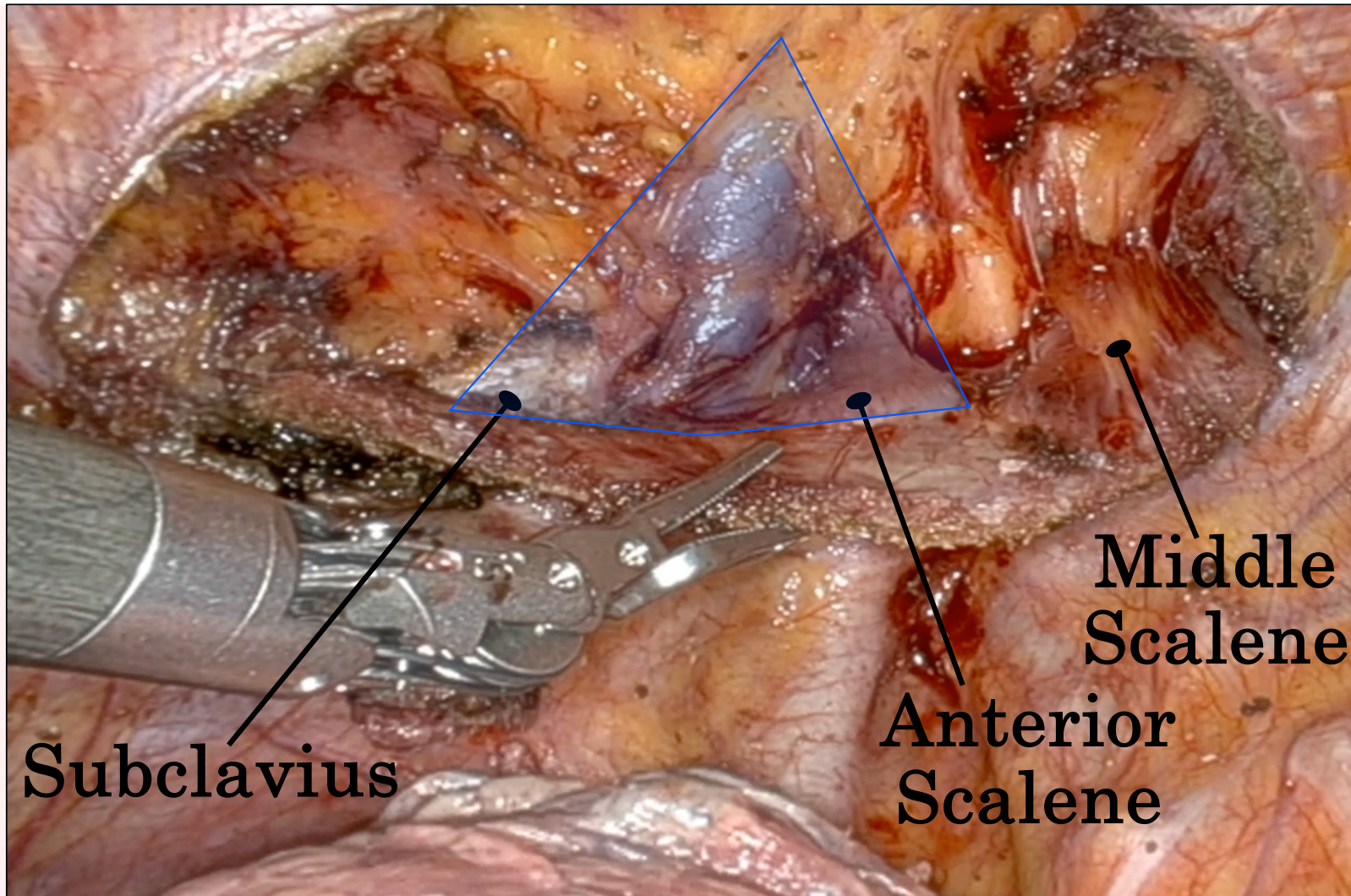
6. Enter the Thoracic Outlet



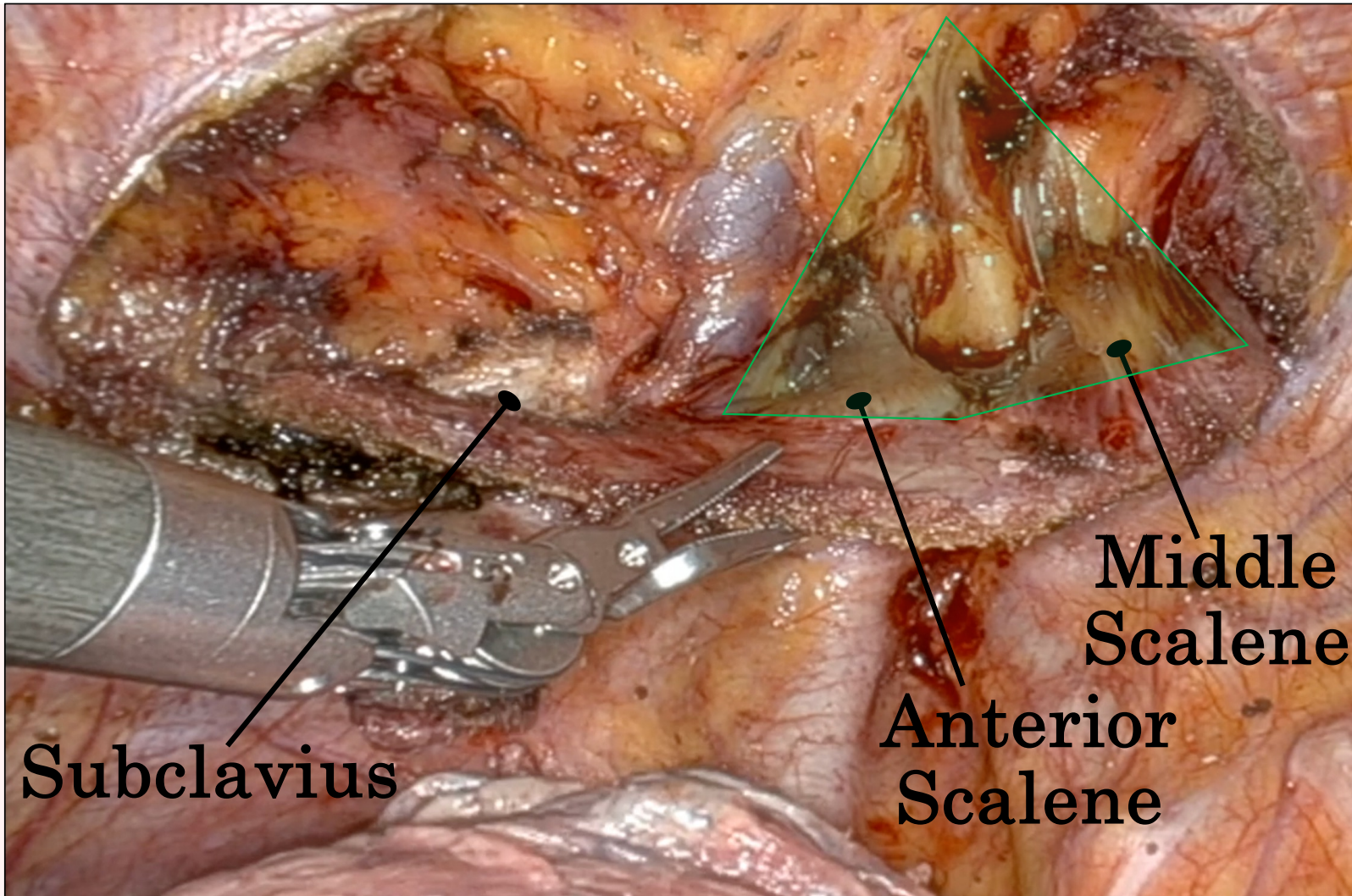
Revisit Anatomy



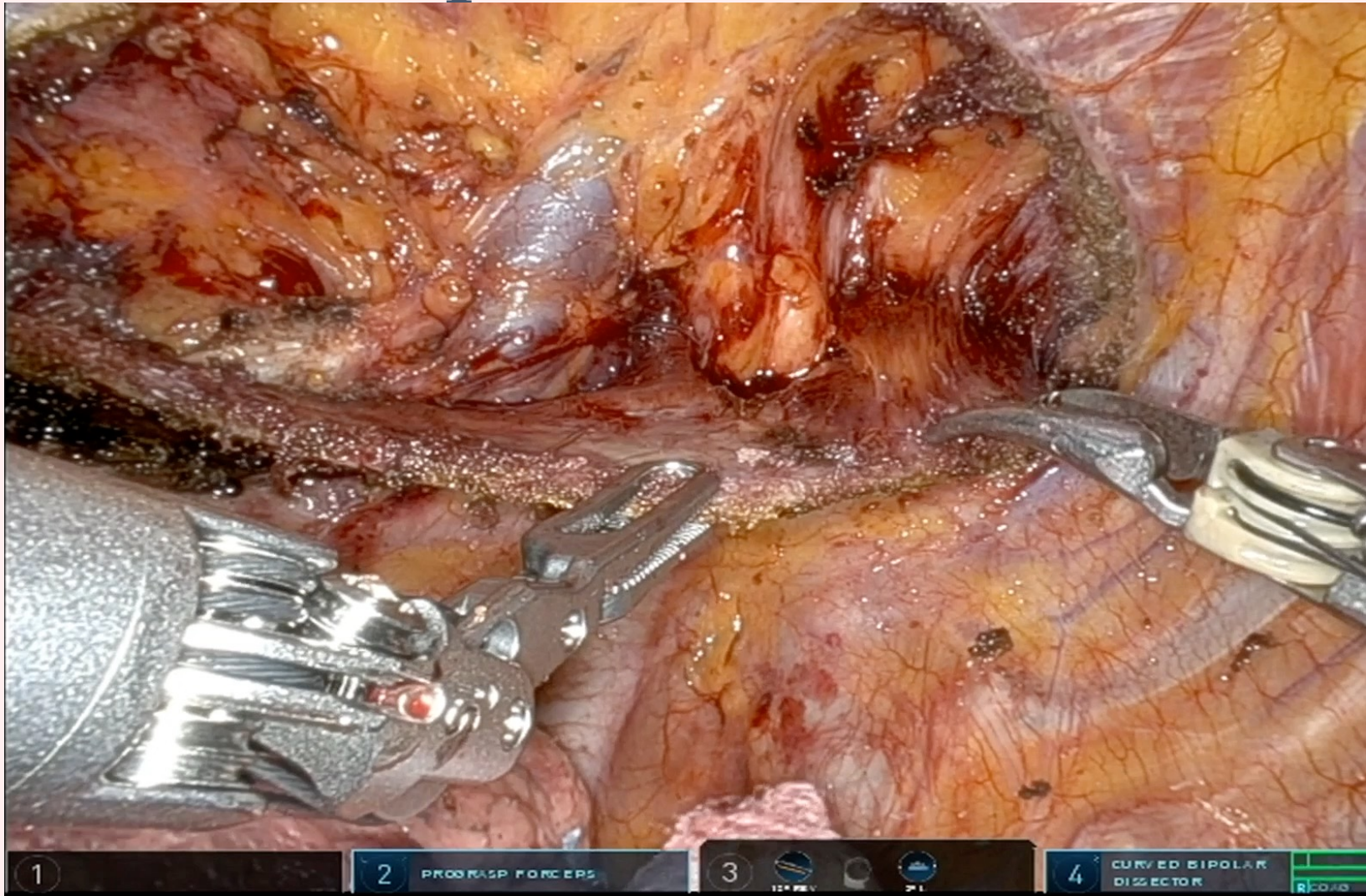vTOS



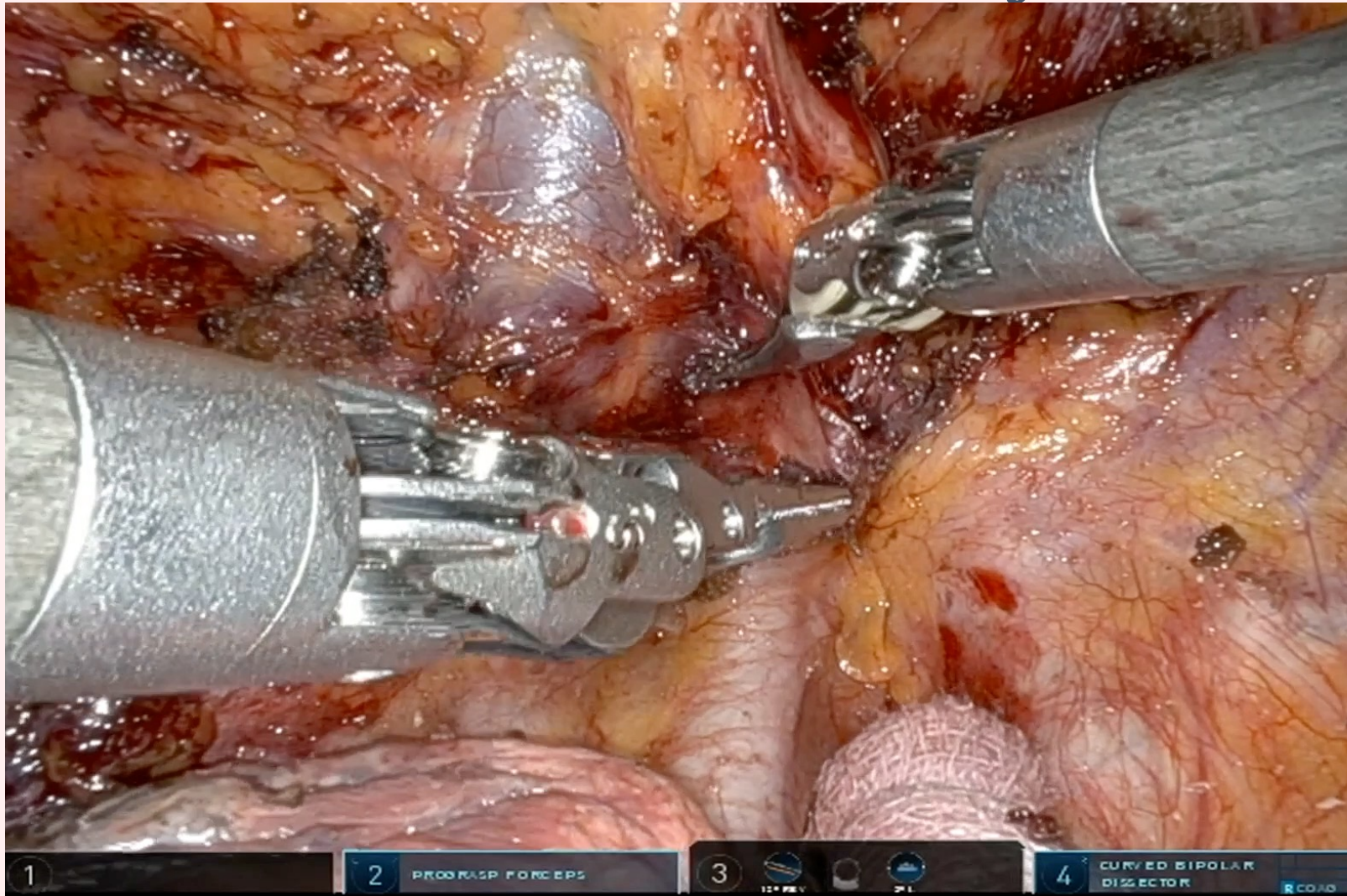
nTOS



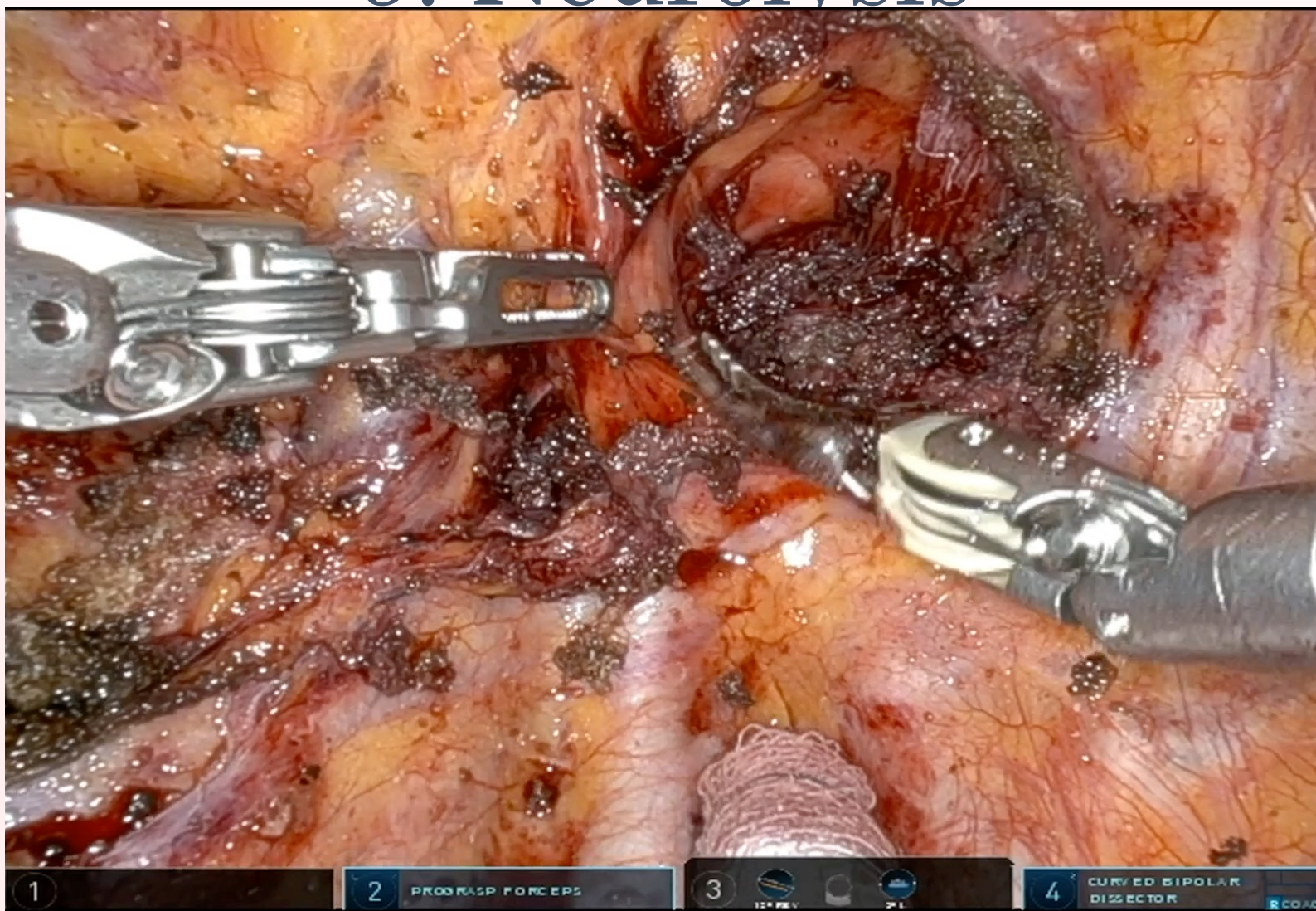
7. Separation of Rib



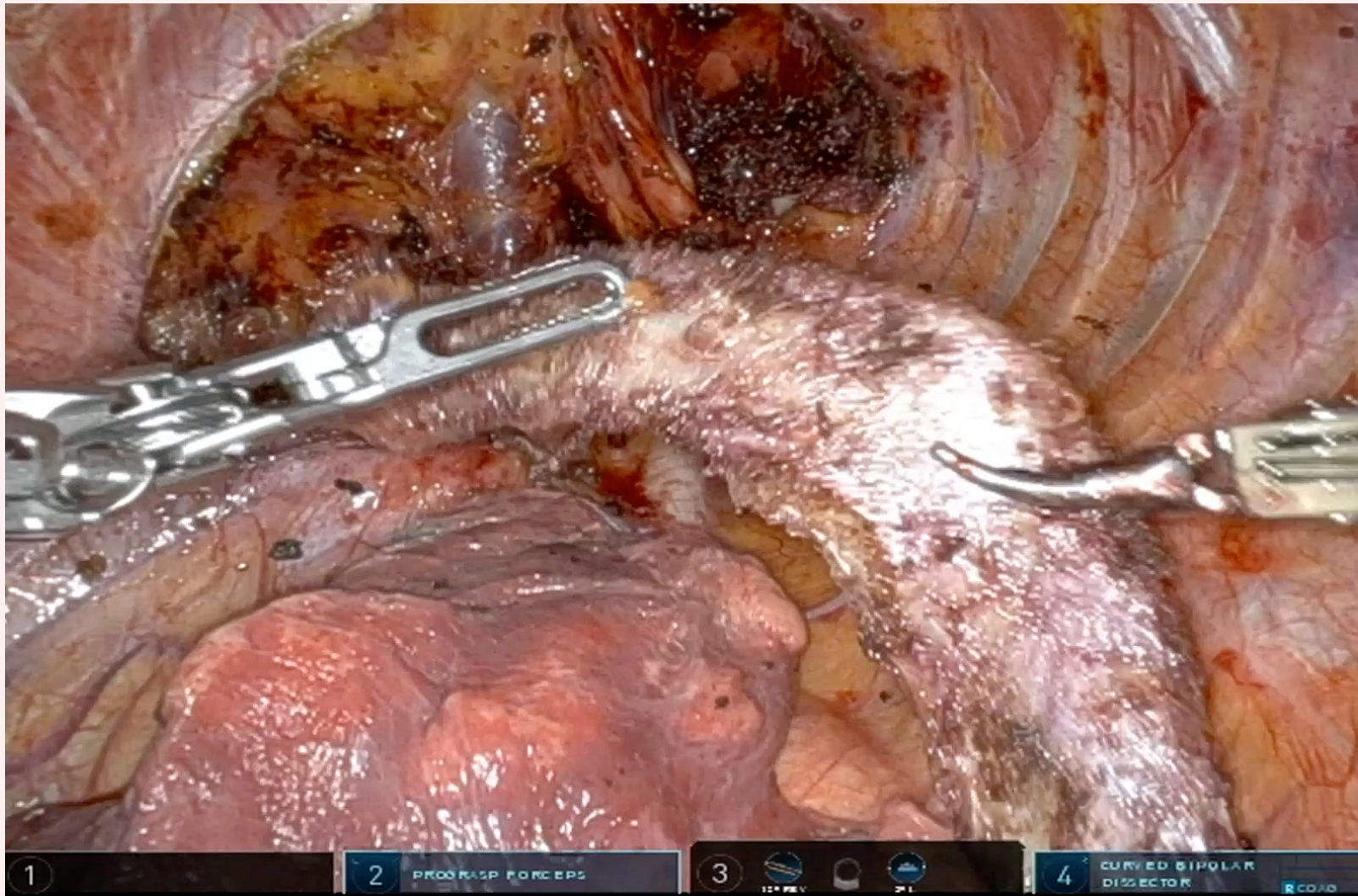
8. Scalenectomy



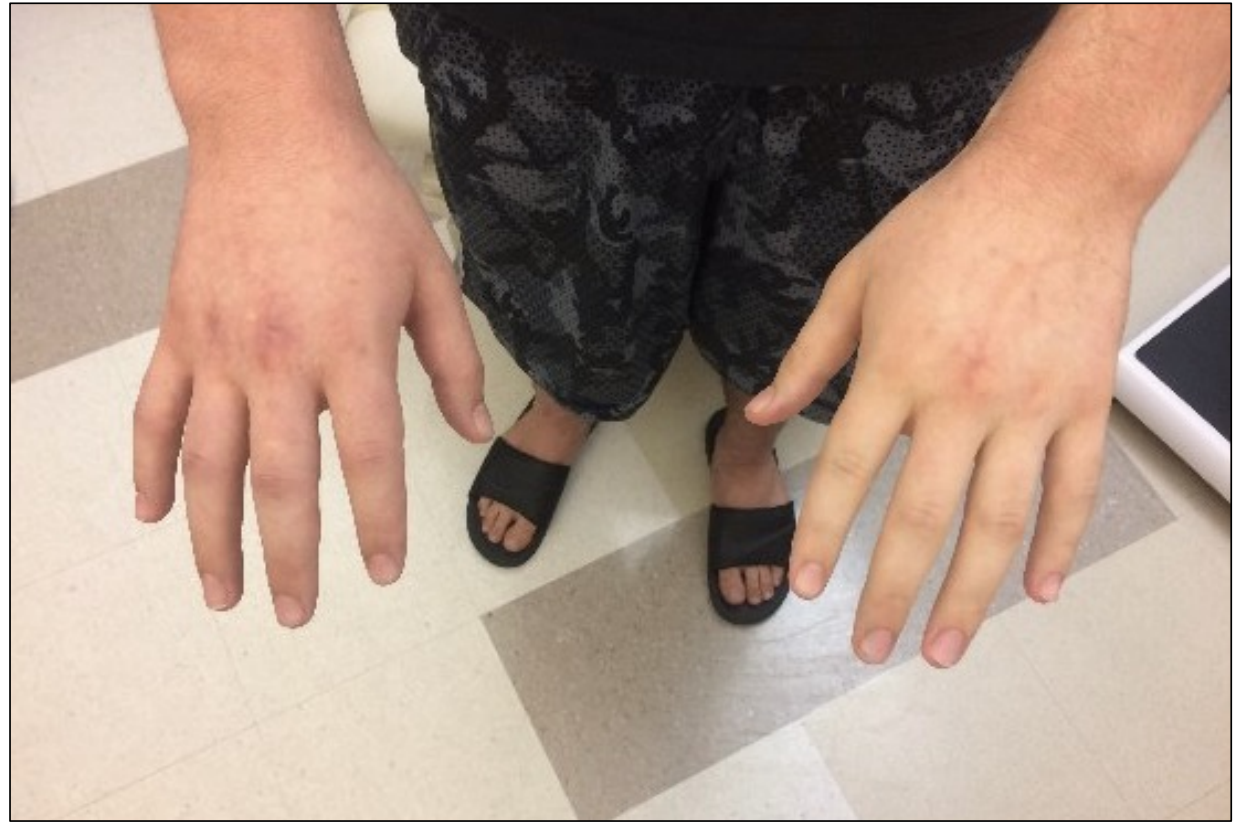9. Neurolysis




10. Closure



vTOS

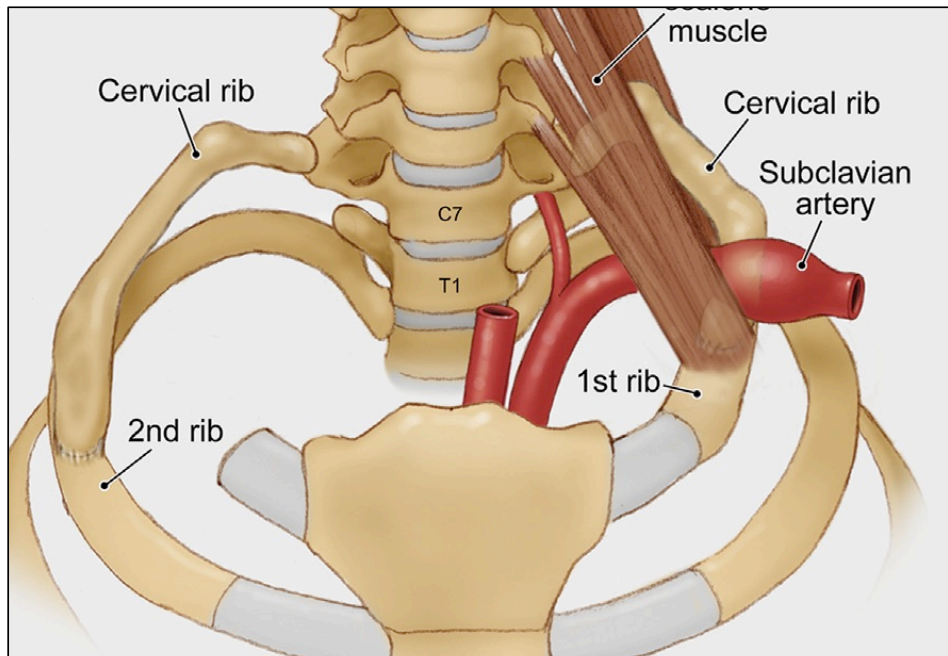


Venolysis



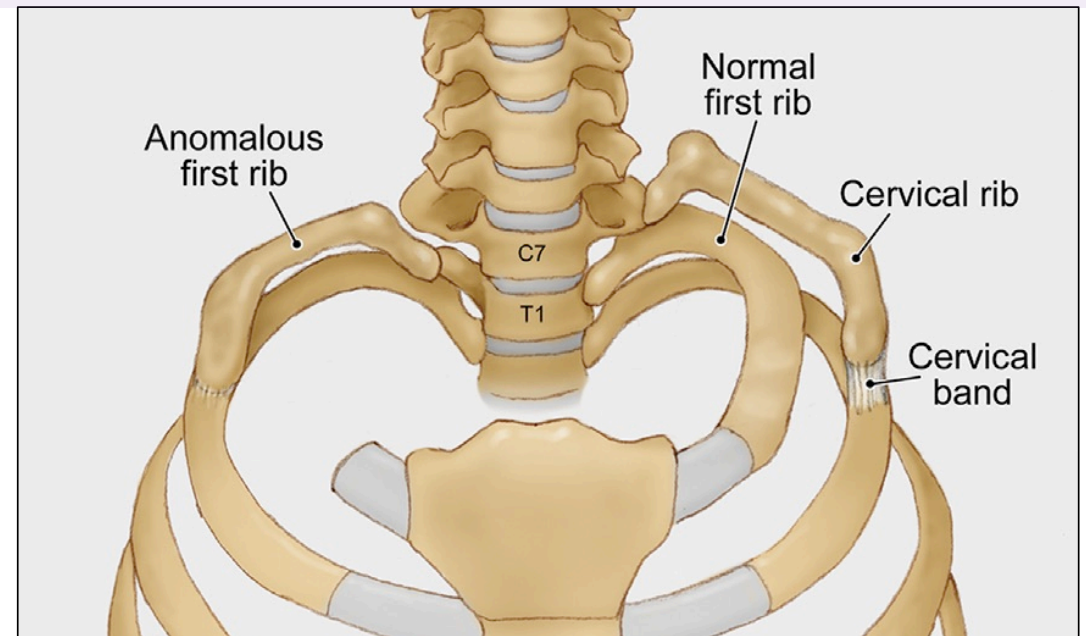
nTOS

Cervical Rib



Complete ~1/3

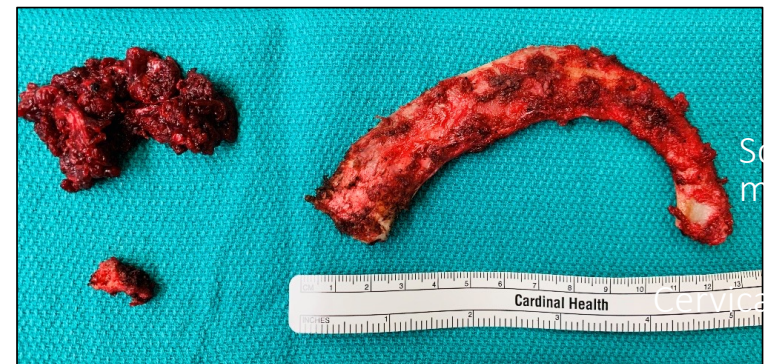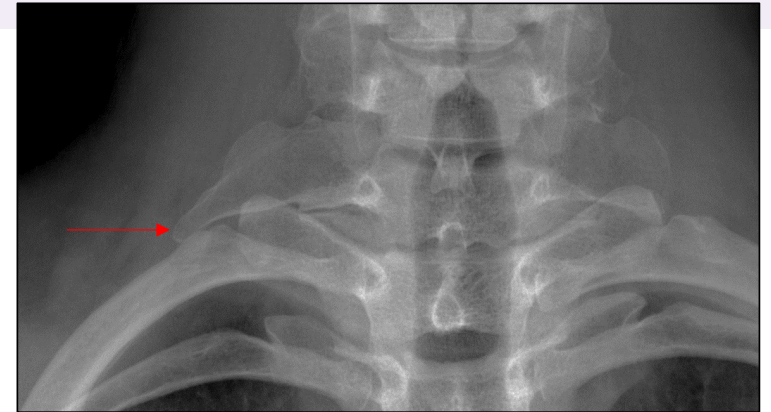
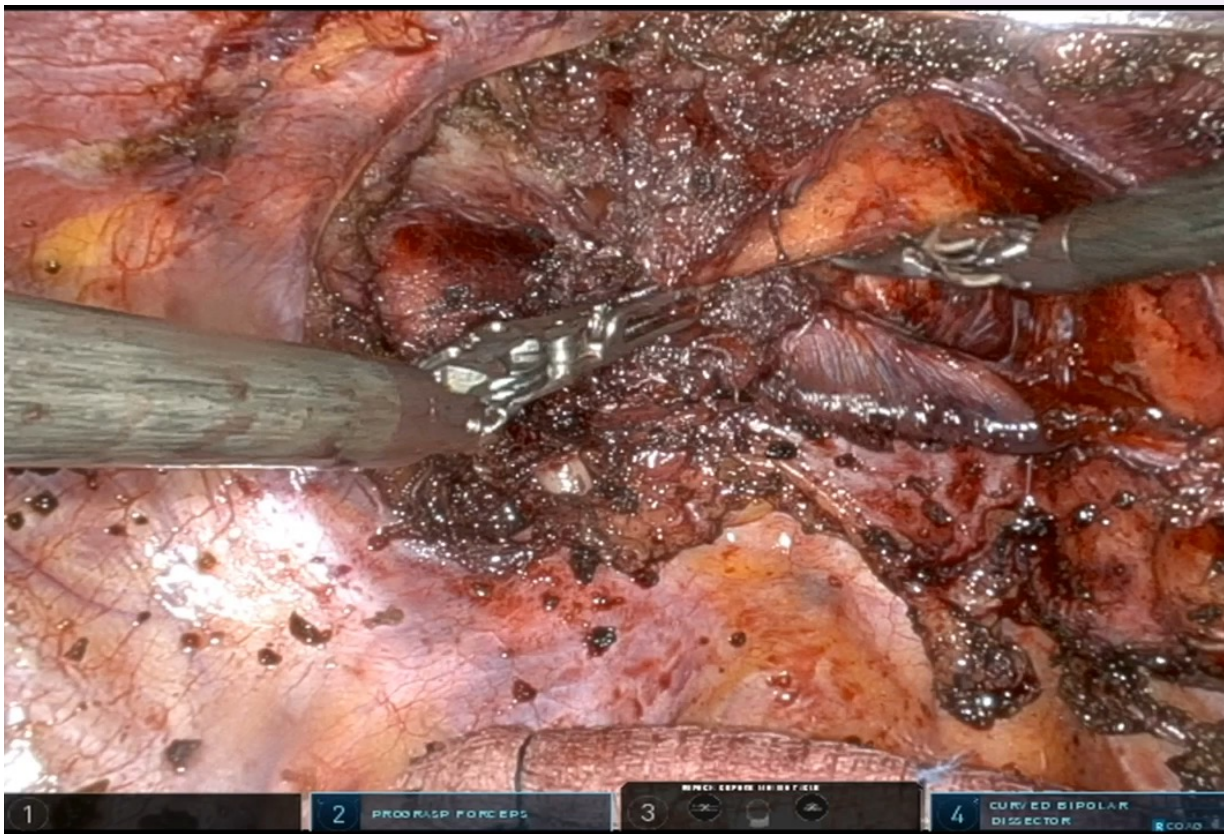
- 1.1% in cadavers
- 1-10% in nTOS
- W:M 2:1
- BL 48%



Incomplete ~2/3

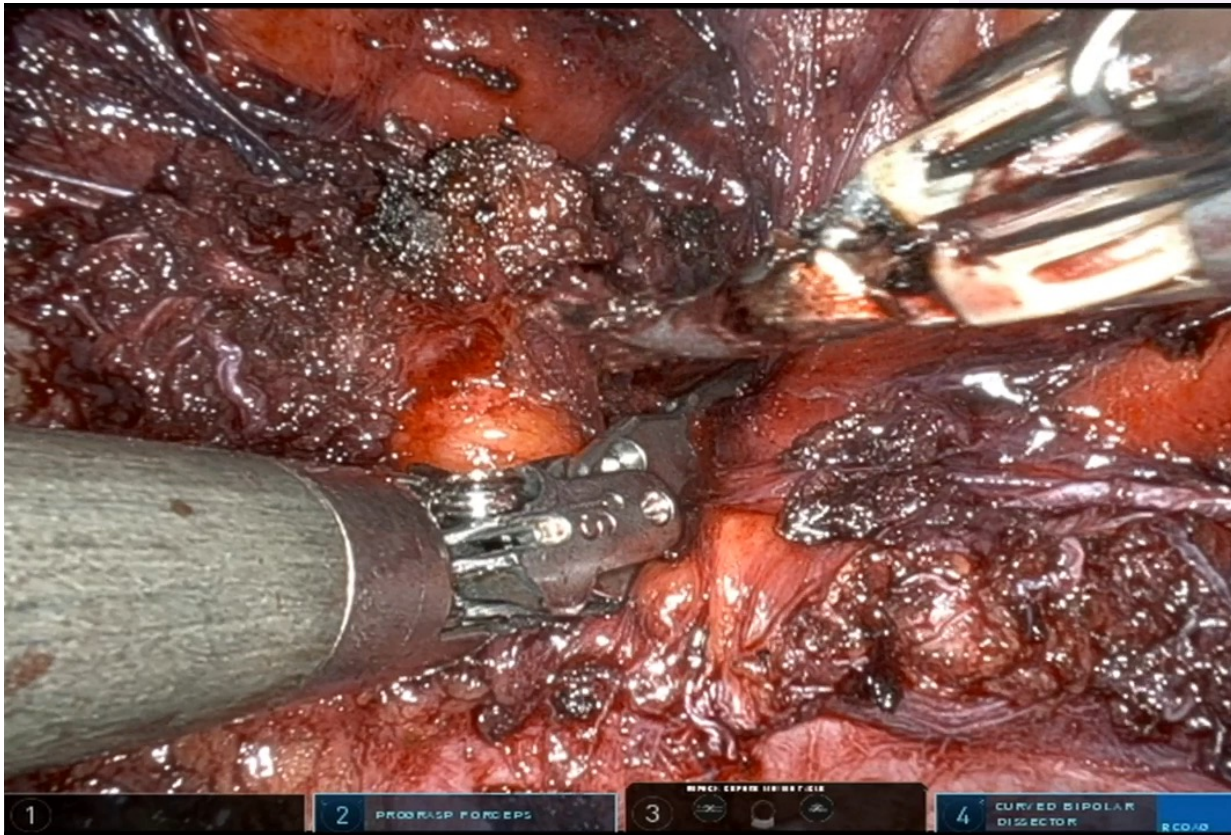
nTOS

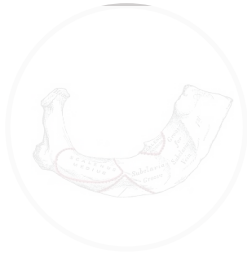
Cervical Rib



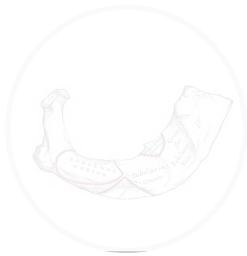nTOS

Cervical Rib

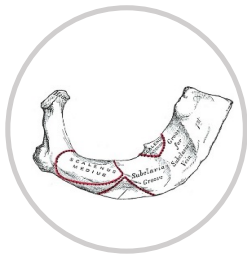




Background & Rationale



Operation (3 cases)



Results



Advantages of Robotic FRR

Outstanding Exposure of the First Rib

No Retraction of Neurovascular Structures

Improvement in Pain & Disability

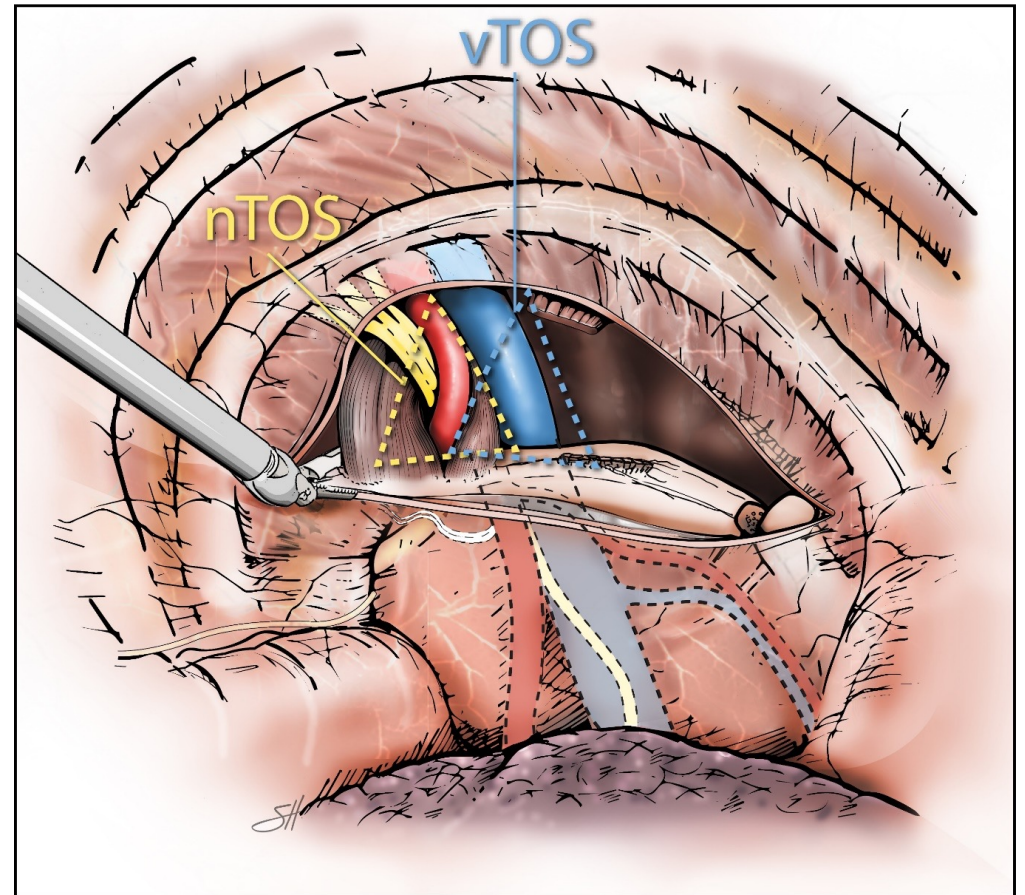


Illustration: Scott Holmes, BCM

Advantages of Robotic FRR

Outstanding Exposure of the First Rib

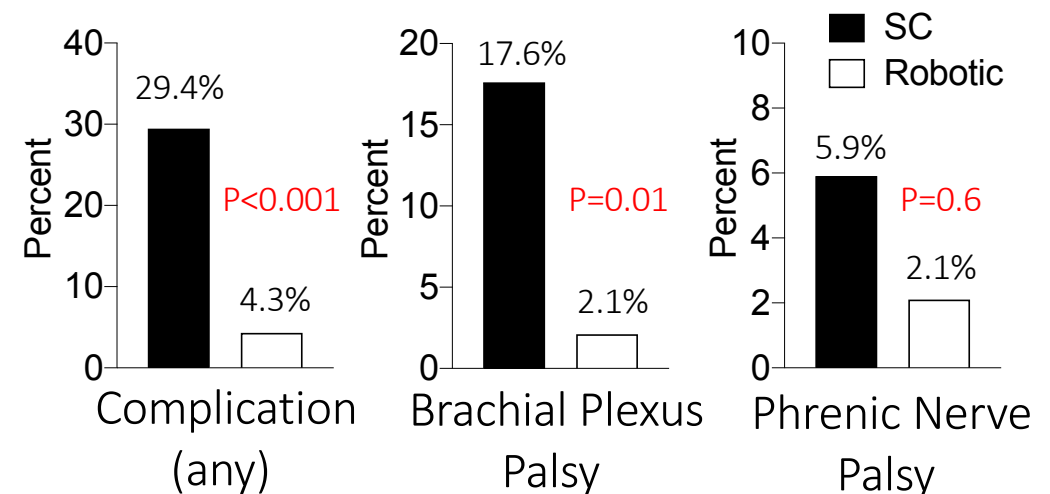
No Retraction of Neurovascular Structures

Improvement in Pain & Disability

Safety of robotic first rib resection for thoracic outlet syndrome

Bryan M. Burt, MD,^a Nihanth Palivela, BS,^a Davut Cekmecelioglu, MD,^a Paul Paily, MD,^c Bijan Najafi, PhD,^b Hyun-Sung Lee, MD, PhD,^a and Miguel Montero, MD^b

JTCVS 2021



Advantages of Robotic FRR

Outstanding Exposure of the First Rib

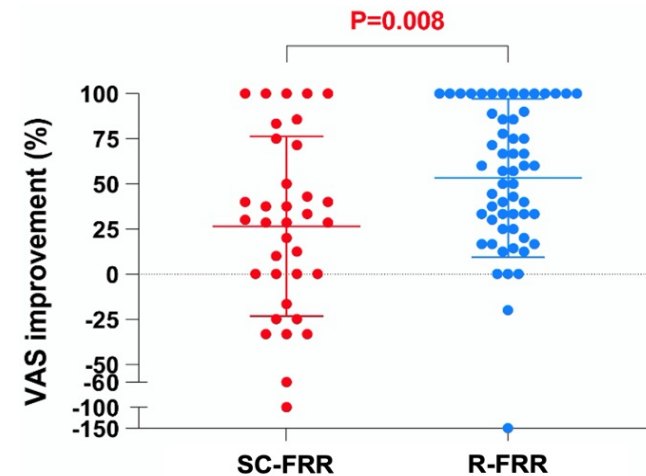
No Retraction of Neurovascular Structures

Improvement in Pain & Disability

Immediate Post-op (In Hospital)

Variables	R-FRR cases (n = 72)	SC-FRR cases (n = 51)	P value
In-hospital VAS score	4.7 (1.3)	5.2 (1.2)	.049
MME	37.5 (42.1)	81.1 (59.0)	<.001
at POD1	28.0 (34.3)	49.7 (48.8)	<.001
at POD2	6.0 (12.5)	22.0 (34.5)	<.001

Early Post-op (Clinic)



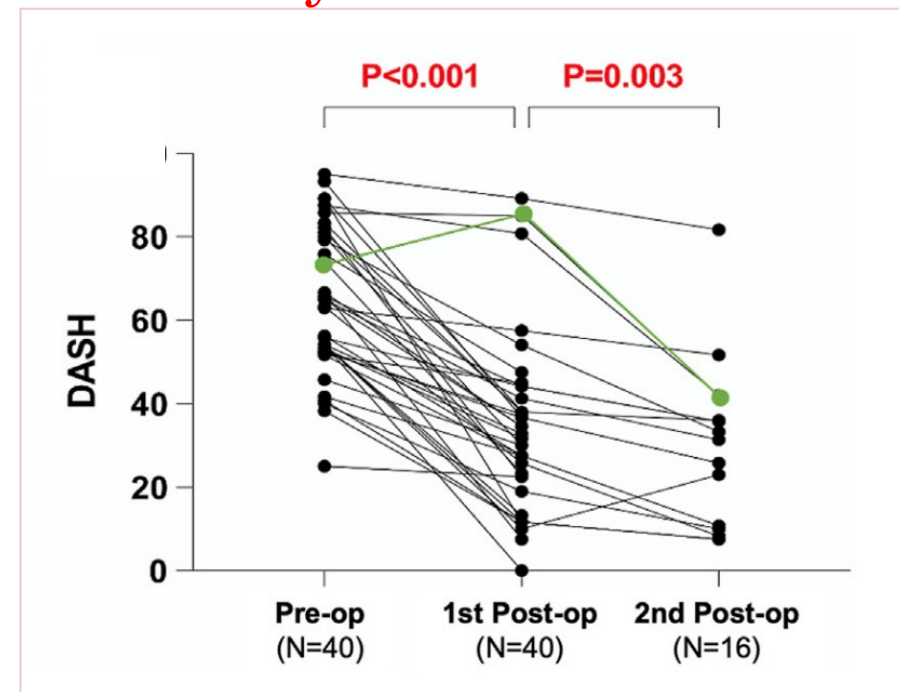
Advantages of Robotic FRR

Outstanding Exposure of
the First Rib

No Retraction of
Neurovascular Structures


Improvement in Pain &
Disability

Disability

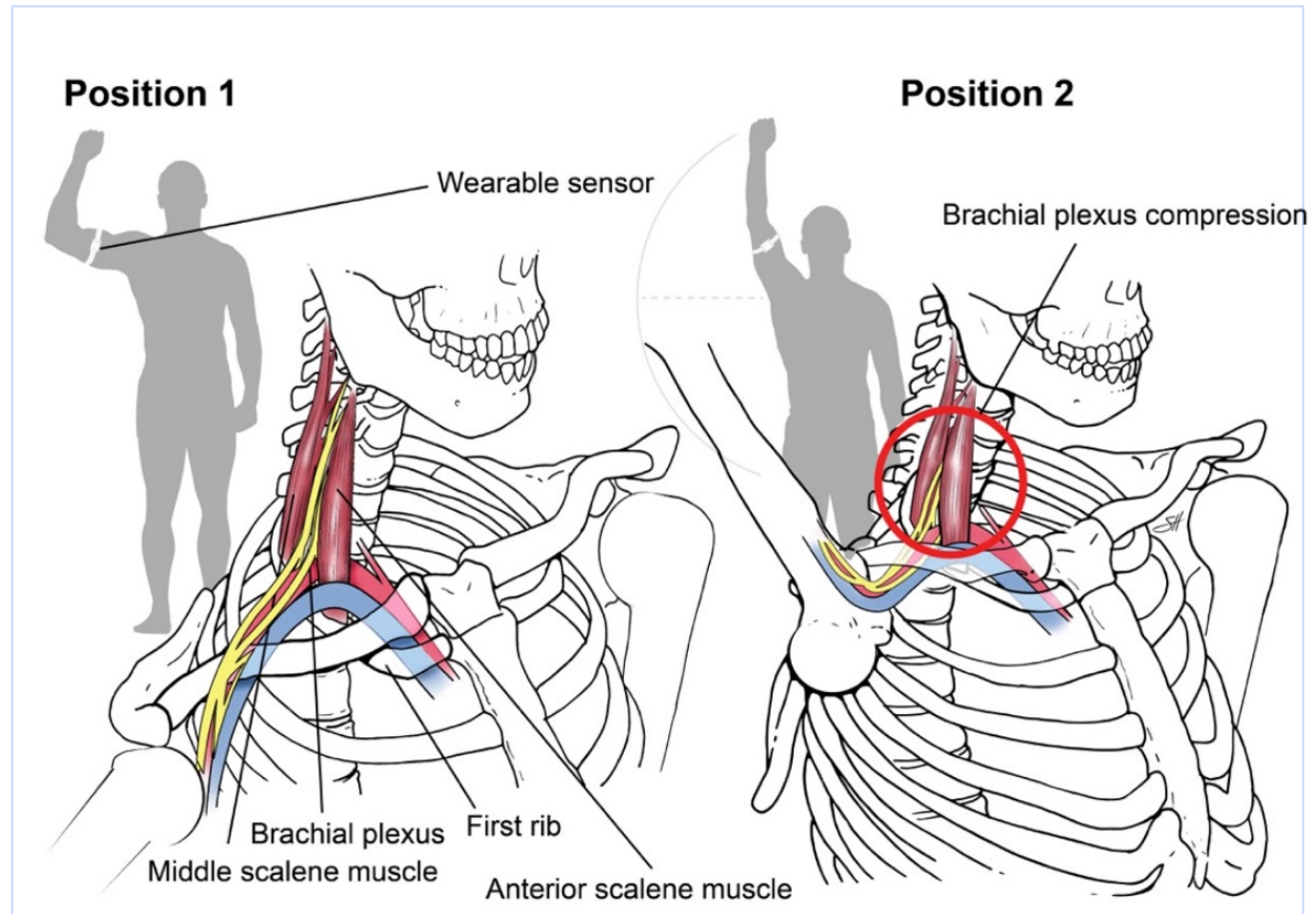


Palivela, Lee, ...Burt. Ann Thorac Surg 2021

Digital Biomarkers of TOS-impacted Function



Baylor College of Medicine
Bijan Najafi, PhD
Professor of Surgery

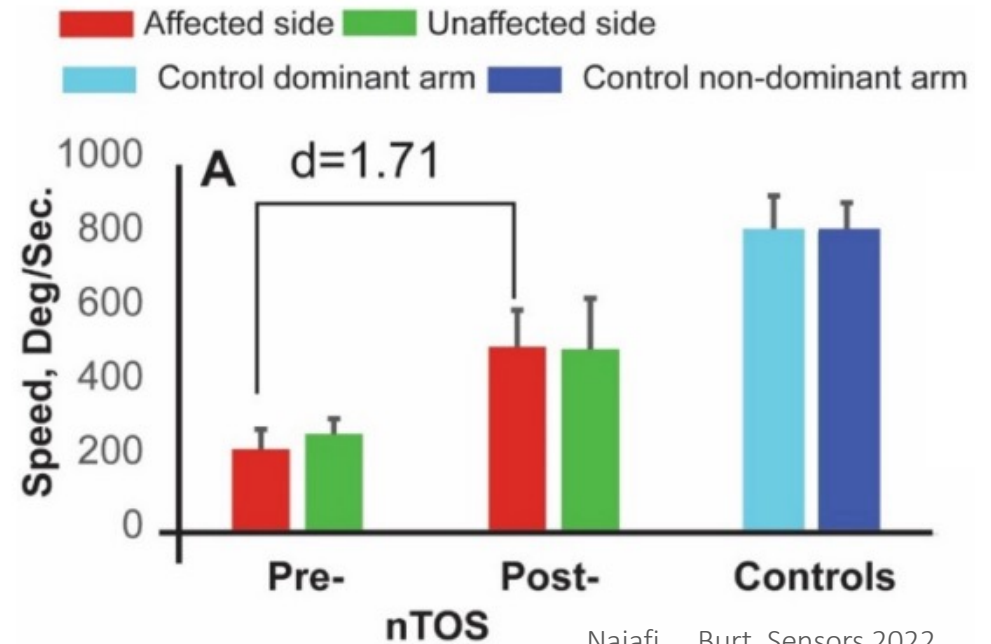
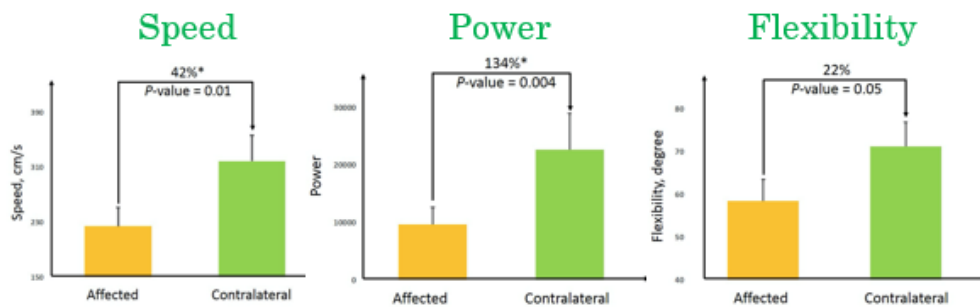


Najafi, ...Burt. Sensors 2022

Problem: Lack of a reproducible test to measure objective response to nTOS therapy

Digital Biomarkers of TOS-impacted Function

60-sec Office Test

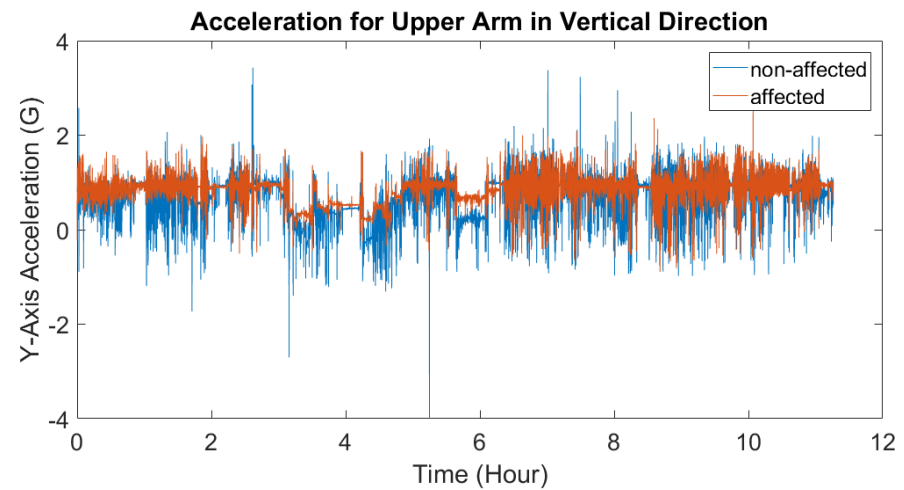
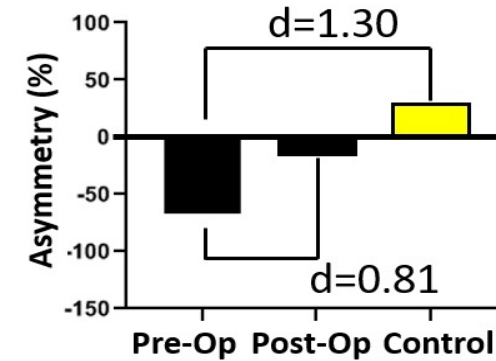
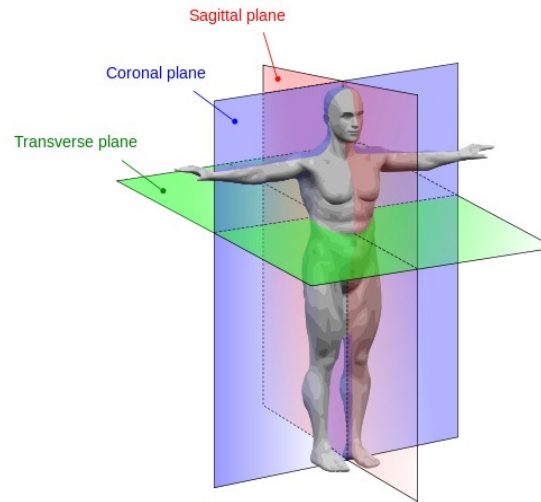
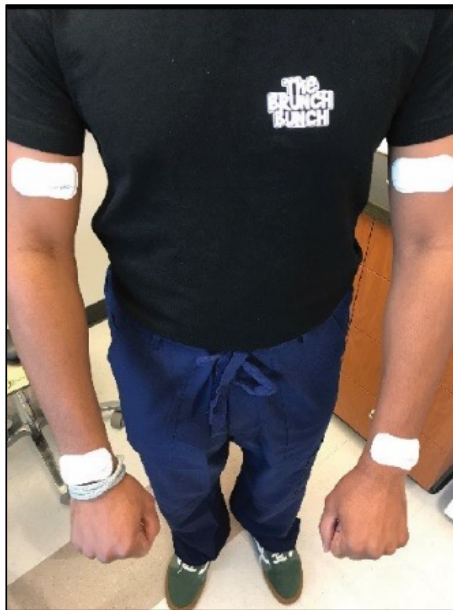
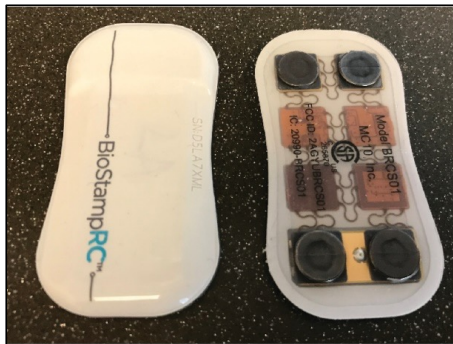
Najafi, ...Burt. Sensors 2022

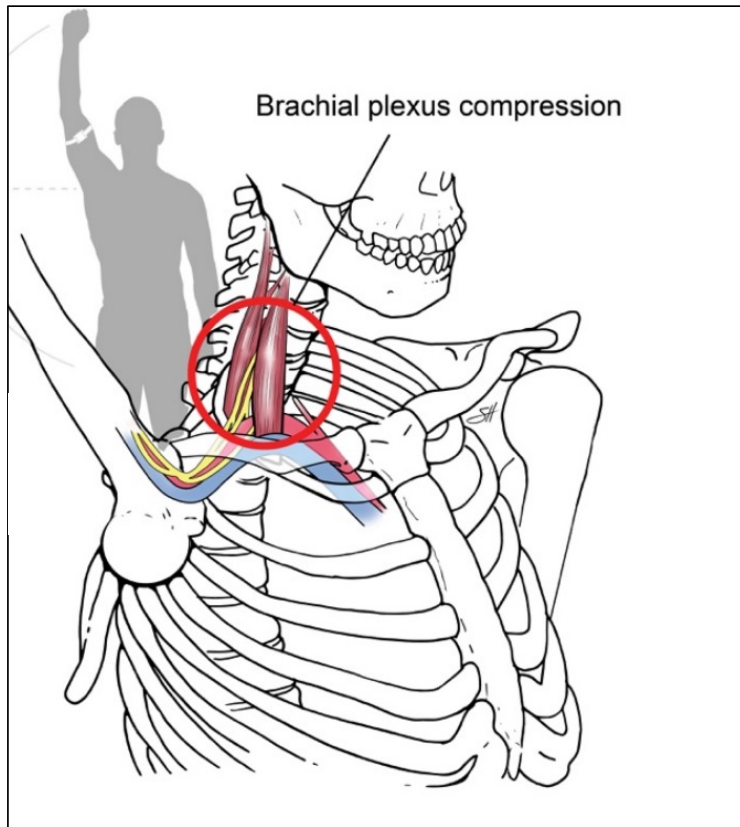
Problem 1: Lack of a reproducible test to measure objective response to nTOS therapy

Digital Biomarkers of TOS-impacted Function

24h At-home Test

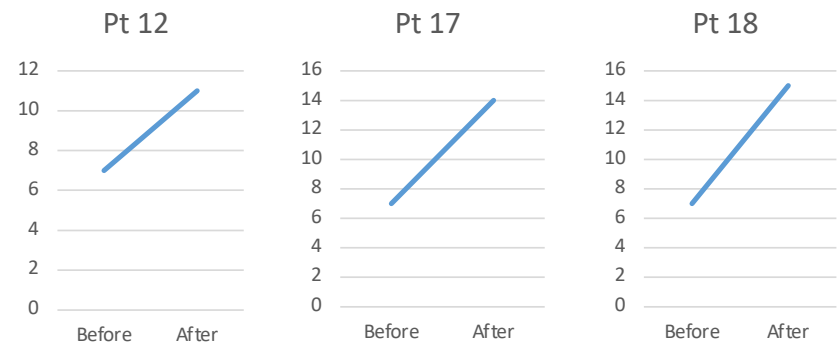


Digital Biomarkers of TOS-impacted Function

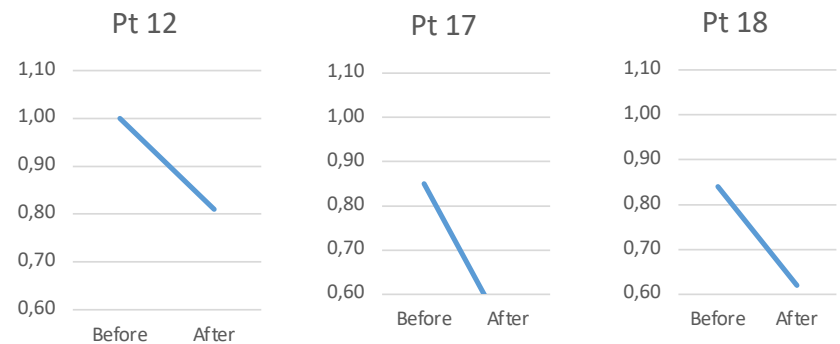


Function after Scalene Muscle Block

Cycles

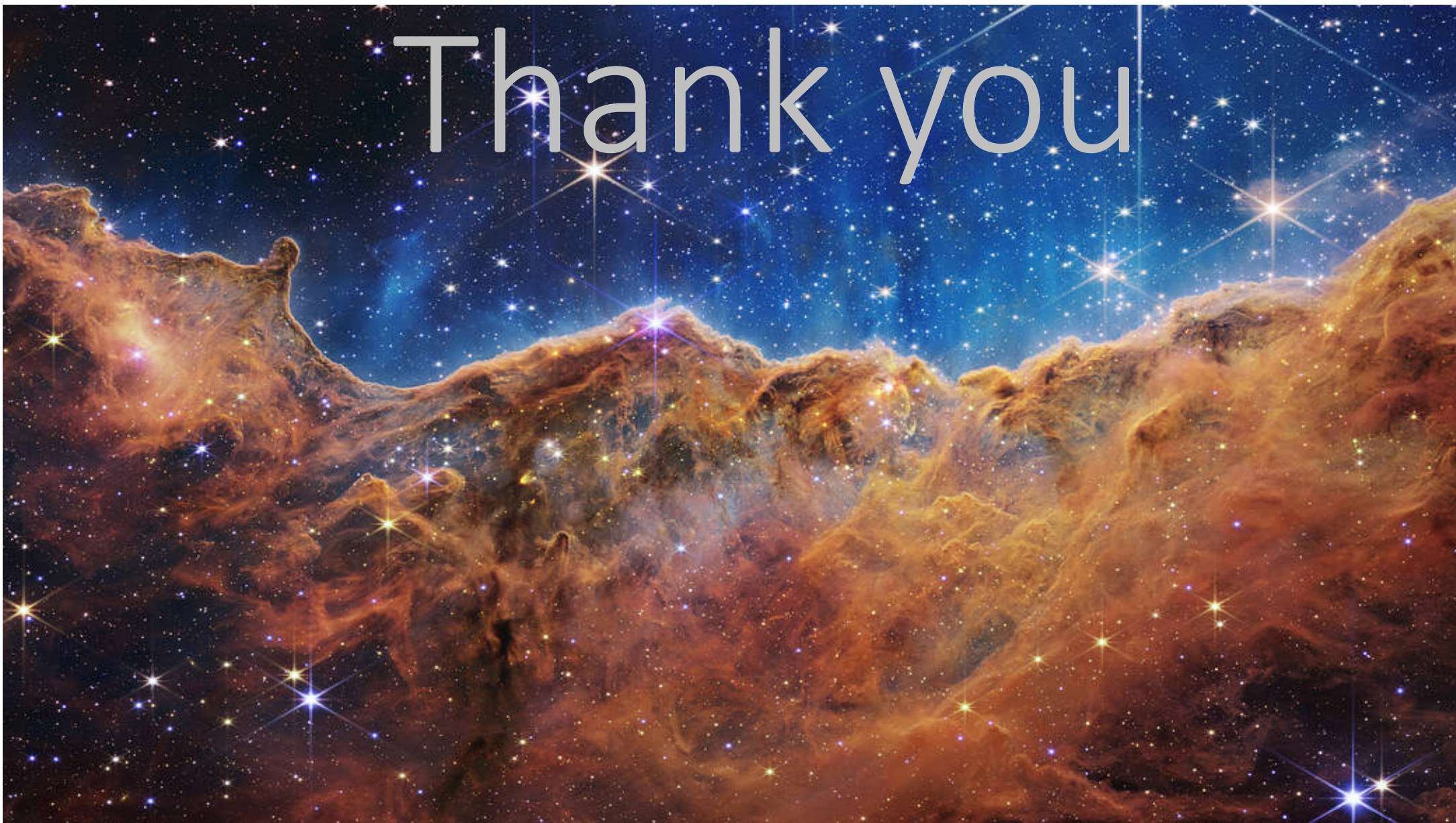

Weakness



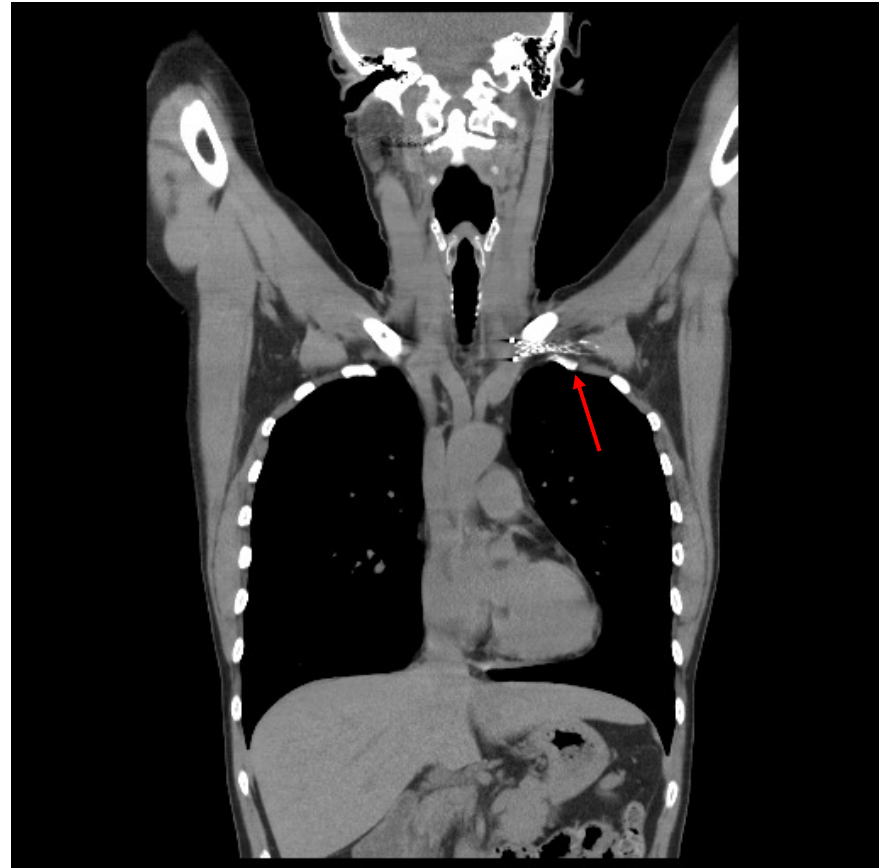Problem 2: No objective test to diagnose NTOS

Thank you



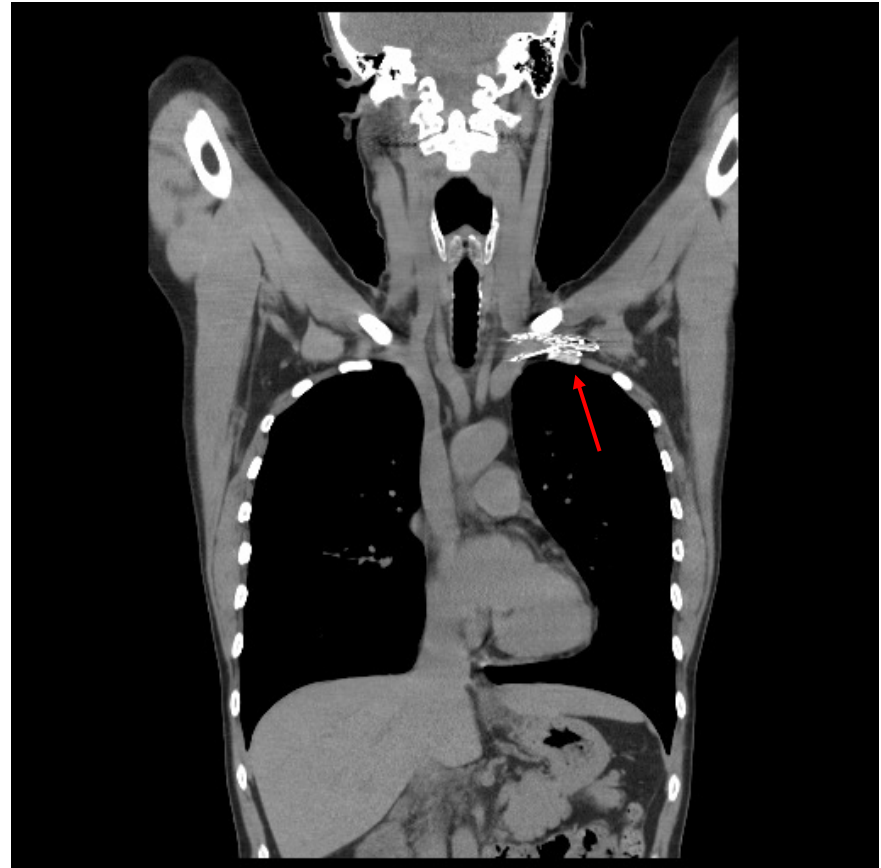Recurrent TOS

- 48y F
- vTOS w thrombosis
- Thrombolysis
- Left supraclavicular FRR x2
- Left subclavian stent
- Left neck & arm swelling



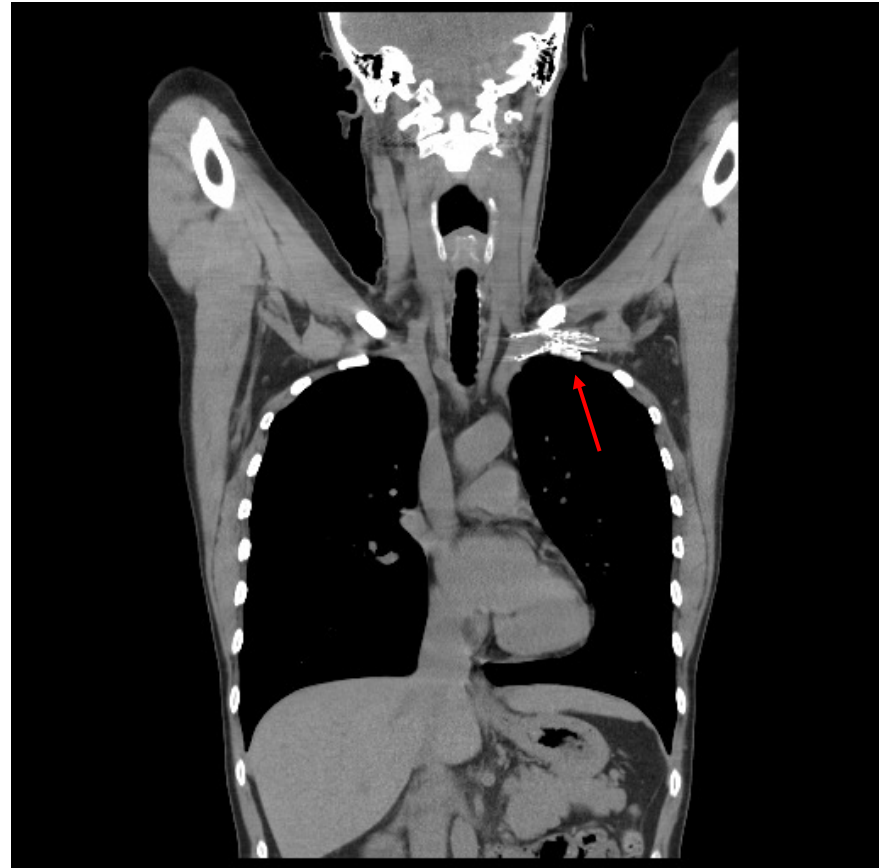
Case 3: recurrent TOS

- 48y F
- vTOS w thrombosis
- Thrombolysis
- Left supraclavicular FRR x2
- Left subclavian stent
- Left neck & arm swelling



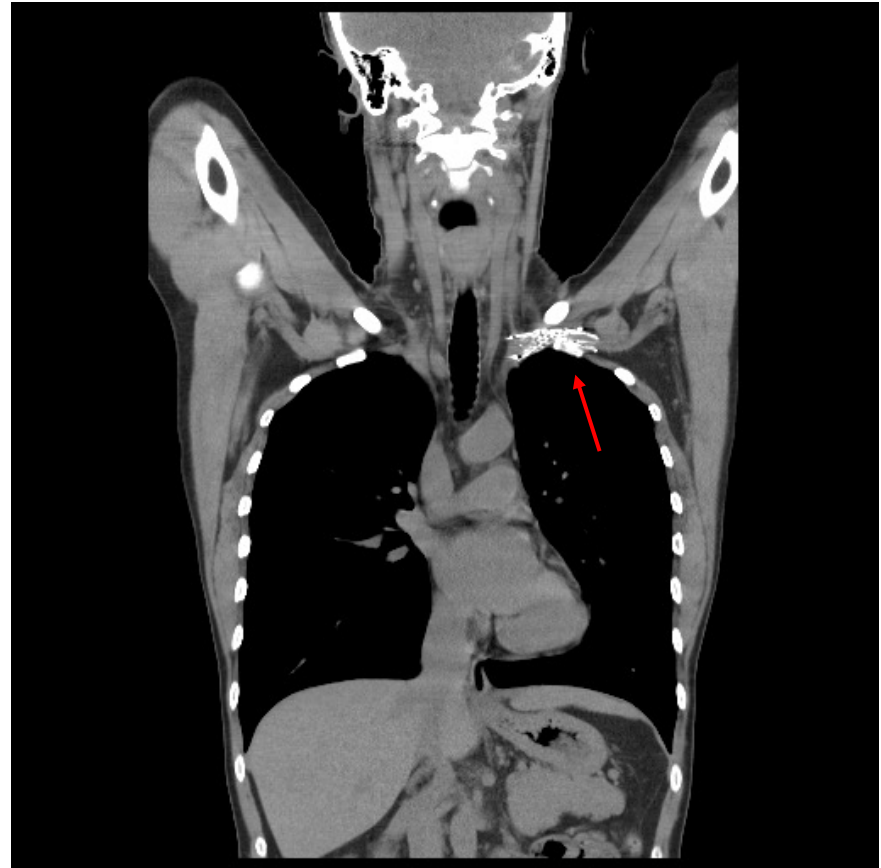
Case 3: recurrent TOS

- 48y F
- vTOS w thrombosis
- Thrombolysis
- Left supraclavicular FRR x2
- Left subclavian stent
- Left neck & arm swelling



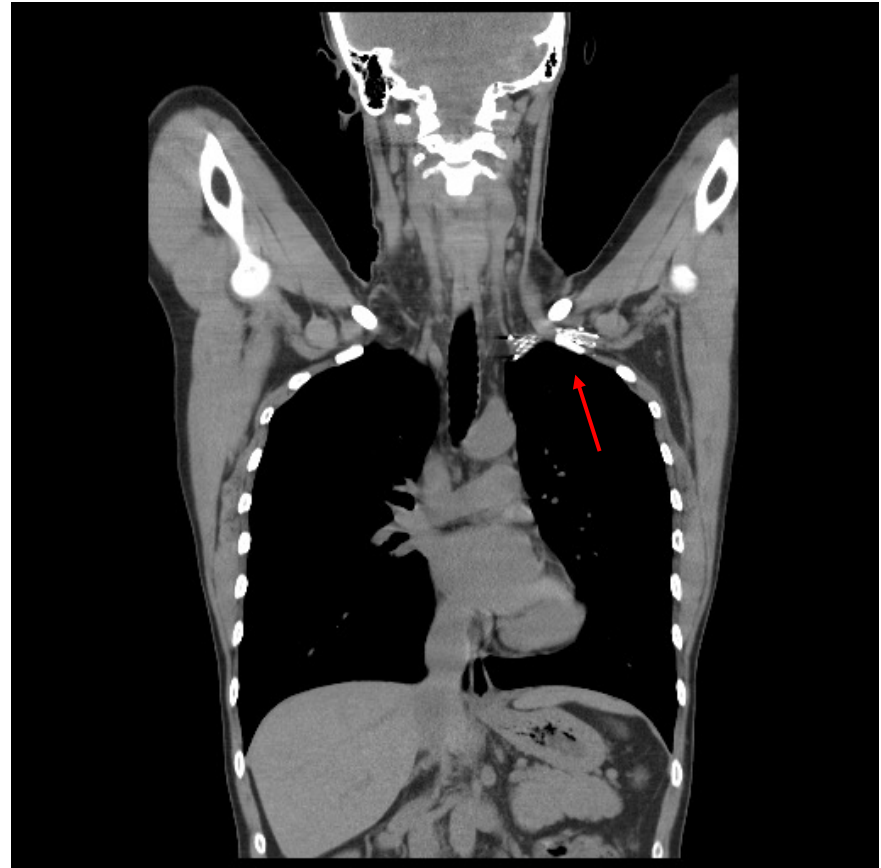
Case 3: recurrent TOS

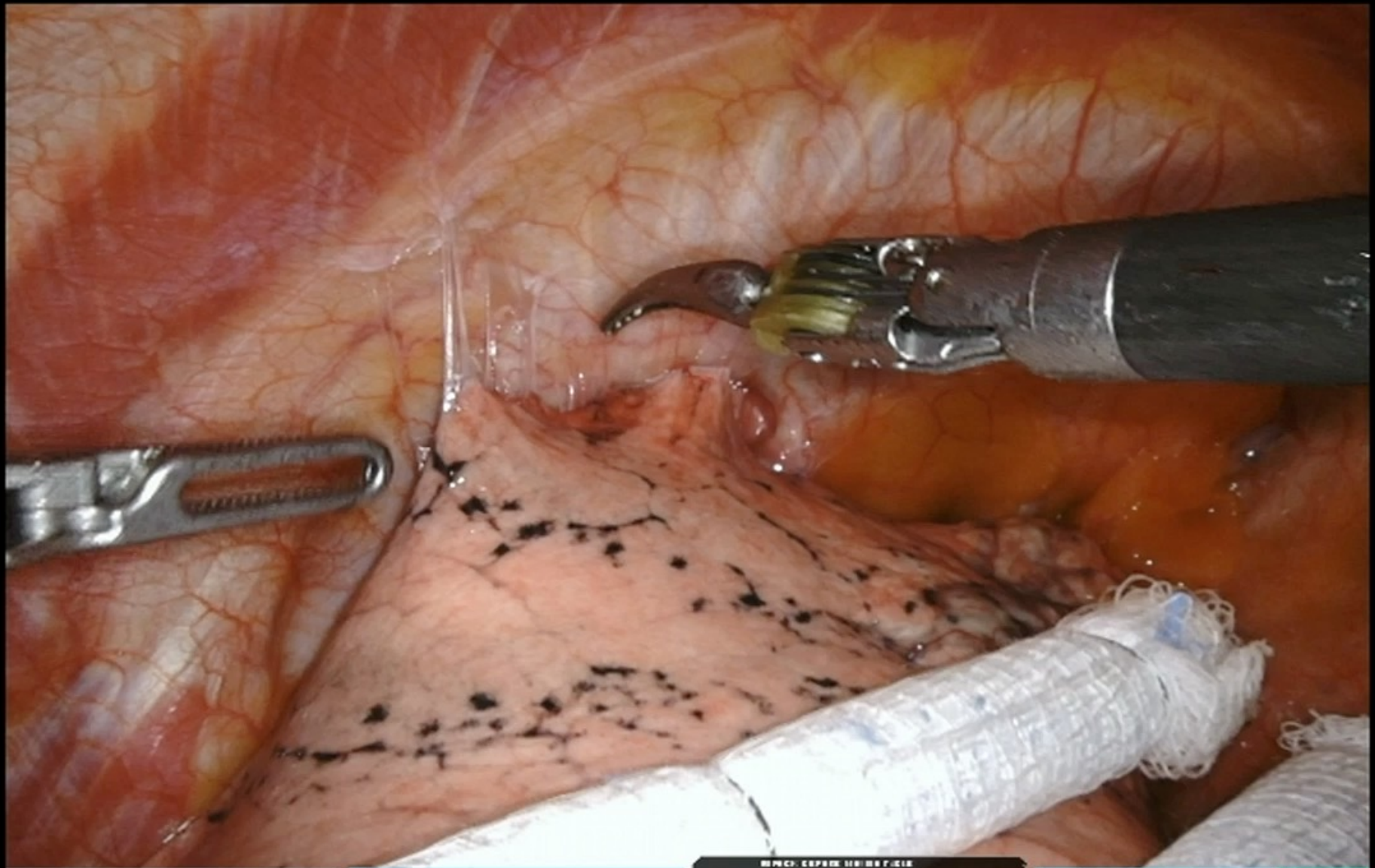
- 48y F
- vTOS w thrombosis
- Thrombolysis
- Left supraclavicular FRR x2
- Left subclavian stent
- Left neck & arm swelling



Case 3: recurrent TOS

- 48y F
- vTOS w thrombosis
- Thrombolysis
- Left supraclavicular FRR x2
- Left subclavian stent
- Left neck & arm swelling





1 2 PROORASP FORCEPS 3 4 CURVED BIPOLAR DISSECTOR